

# Oral leukoplakia: demographic, clinical and histopathological characteristics

## Oral lökoplakiler: Demografik, klinik ve histopatolojik özellikler

Ecem Bulut Okut<sup>1</sup>, Can Ceylan<sup>2</sup>

<sup>1</sup>Tinaztepe Galen Hospital, Izmir, Turkey, <sup>2</sup>Dept of Dermatology, Ege University Faculty of Medicine, Izmir, Turkey

### Abstract

**Objective** Oral leukoplakia (OL) is the most common precancerous lesion of the oral mucosa with an etiology mainly related to tobacco and alcohol use. Although the most common location is the buccal mucosa, it may also affect other areas of the oral mucosa. Histopathologically, the spectrum of lesions ranges from squamous hyperplasia unaccompanied by dysplasia, to that with mild, moderate and severe dysplasia. The greatest determinant of malignant transformation is the presence of dysplasia and its severity.

**Methods** This is a retrospective study and, data of the patients receiving clinical and histopathological diagnosis of oral leukoplakia at the Council for Facial and Mouth Lesions at Ege University Faculty of Medicine (EGEYA) between 2007 and 2015 was used including demographic details accessed from council information forms and photo archives.

**Results** Of the 79 patients, 40 were male (50.6%) and 39 (49.4%) were female. Patients were aged between 18-91, with a mean overall age of  $58.73 \pm 17.95$  years. Evaluation of the risk factors revealed that 45 patients (56.9%) were smokers, and alcohol was regularly consumed by 22 patients (27.8%). Most of the lesions were located in the buccal mucosa (34.4%). Homogenous OL was seen in 39 patients (49.4%) and nonhomogeneous OL in 40 patients (50.6%). The most reported histologic diagnosis was 37 (46.8%) cases of squamous hyperplasia (SH) and hyperkeratosis.

**Conclusion** To minimize the risk of malignant transformation in leukoplakia lesions, the elimination of risk factors and early biopsy is essential.

**Key words:** oral leukoplakia, oral premalignant lesion, epidemiology

### Özet

**Amaç** Oral lökoplaki (OL), oral mukozanın en yaygın prekanseröz lezyonudur. Etiyolojide en sık sorumlu tutulan faktörler, tütün ve alkol kullanımınıdır. En yaygın yerleşim bölgesi bukkal mukoza olmakla birlikte, oral mukozanın diğer bölgelerini de tutabilir. Histopatolojik olarak lezyon spektrumu, displazinin eşlik etmediği skuamöz hiperplaziden; hafif, orta ve şiddetli displaziye kadar değişkenlik gösterebilir. Malign transformasyon riskinin en önemli belirleyicisi ise; displazi varlığı ile displazi derecesidir.

**Corresponding author:** Ecem Bulut Okut, Tinaztepe Galen Hospital, Izmir, Turkey

Phone: +90 555 862 26 56, E-mail: drecebultut@gmail.com

**Received:** 14 November 2019 **Accepted:** 27 December 2019

**Conflicts of Interest:** None

**Funding:** None



This work is licensed under a Creative Commons Attribution-NonCommercial 4.0 International License.

**Yöntem** Çalışmamızda, 2007-2015 yılları arasında Ege Üniversitesi Tıp Fakültesi yüz ve ağız lezyonları (EGEYA) konseyinde; klinik ve histopatolojik olarak oral lökoplaki tanısı alan hastalar, konsey bilgi formları ve fotoğraf arşivi üzerinden, hastaların demografik özellikleri de dikkate alınmak suretiyle, retrospektif olarak değerlendirildi.

**Bulgular** 79 hastanın 40'ı (%50.6) erkek ve 39'u (%49.4) kadındı. Hastalar 18 ile 91 yaşları arasında idi, ortalama yaş  $58.73 \pm 17.95$  yılı. Risk faktörleri açısından, 45 hasta (%56.9) sigara içiyor, 22 hasta (%27.8) düzenli alkol tüketiyordu. Lezyonların çoğu bukkal mukozaydı (%34.4). 39 hastada (%49.4) homojen, 40 hastada (%50.6) homojen olmayan OL saptandı. En fazla görülen histolojik tanı 37 hastada (%46.8) skuamöz hiperplazi (SH) ve hiperkeratozdu.

**Sonuç** Lökoplaki lezyonlarında malign transformasyon

riskini en aza indirmek için risk faktörlerinin ortadan kaldırılması ve erken biyopsi alınması önemlidir.

**Anahtar kelimeler:** oral lökoplaki, oral premalign lezyon, epidemiyoloji

## Introduction

Oral leukoplakia (OL) is the most common precancerous lesion of the oral mucosa.<sup>1</sup> The etiology is multifactorial with chief risk factors being tobacco and alcohol usage.<sup>2</sup> In addition, human papillomavirus (HPV), dental restoration, mechanical irritation, candidiasis, low serum vitamin A and carotene are other etiological factors.<sup>3</sup> Meanwhile, the significant number of cases whose cause cannot be determined are known as idiopathic OL.<sup>4</sup>

OL lesions can be located in any part of the mouth; however, the most common site is in the buccal mucosa.<sup>5</sup>

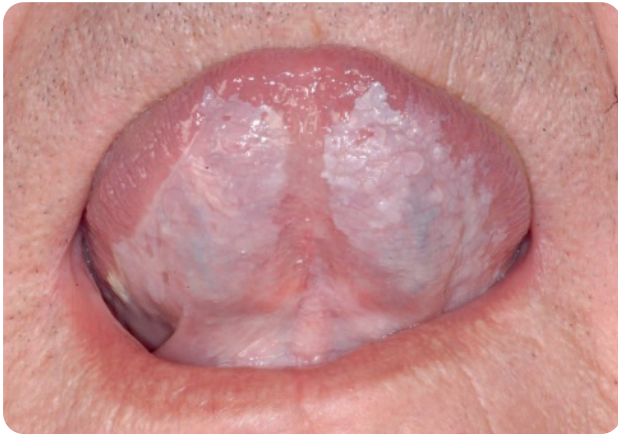


Fig. 1. Thin-flat leukoplakia

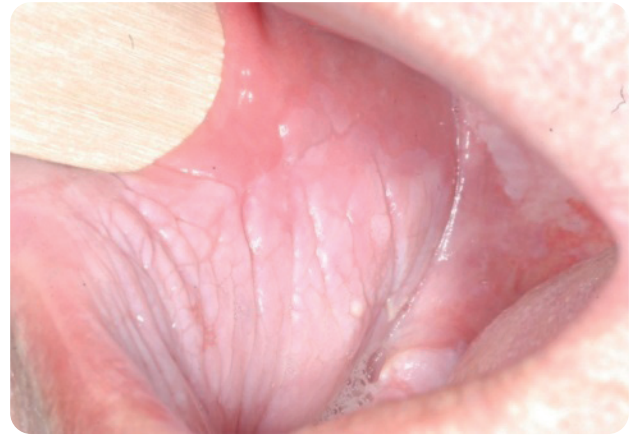

Fig. 2. Thick-fissured leukoplakia

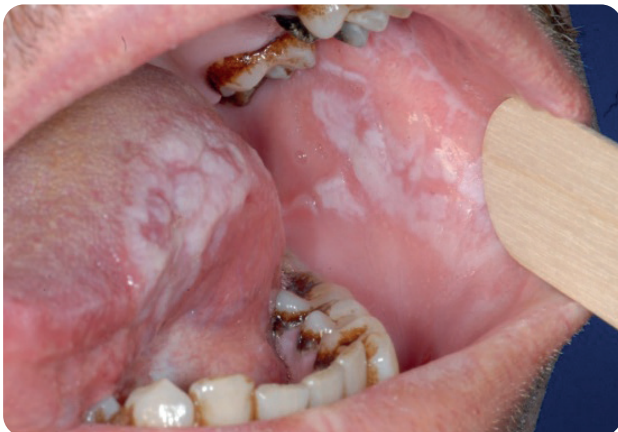

Fig. 3. Granular/nodular leukoplakia

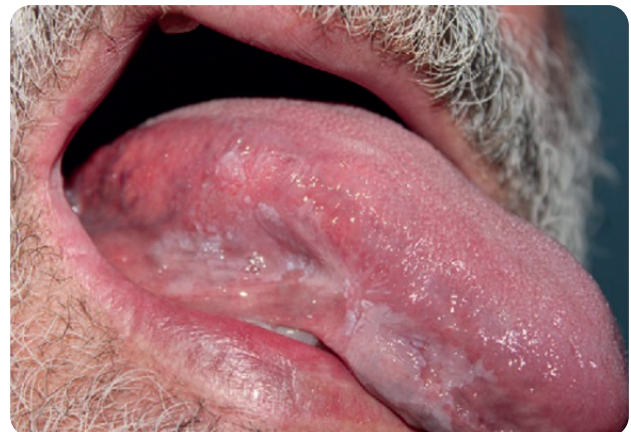

Fig. 4. Erythroleukoplakia

The two main clinical forms of oral leukoplakia, homogenous and non-homogeneous, are differentiated by their surface characteristics and clinical lesion morphologies. Homogenous OL has two subtypes: flat-thin (thickness  $<200\ \mu\text{m}$ ) (Fig. 1) and thick-fissured (thickness  $>200\ \mu\text{m}$ ) (Fig. 2); while there are 3 clinical types of non-homogenous OL: granular nodular (Fig. 3), erythroleukoplakia (Fig. 4) and verrucous. Another important clinical type, proliferative verrucous OL (PVL) is considered a variant of verrucous OL. Rates of post-treatment recurrence and malignant transformation (verrucous carcinoma) in PVL are very high.<sup>6</sup>

Biopsy is an essential step when faced with lesions in the oral mucosa lasting more than 2-4 weeks and suggesting leukoplakia. The biopsy specimen should be taken from areas of erythema, induration or erosion, if present.<sup>7</sup>

Histopathological features of OL may vary from squamous hyperplasia unaccompanied by dysplasia to mild, moderate or severe dysplasia. The presence of dysplasia is considered to be the most important risk factor for malignant transformation.<sup>8</sup> The rate of malignant transformation is reported as 0.13-17.5% depending on geographic region and ethnic characteristics.<sup>9</sup>

In head and neck tumors, carcinogen exposure (e.g. tobacco, alcohol) can lead to premalignant and malignant changes at molecular level in all mucosal areas. This is defined as field cancerization. For this reason, the possibility of multiple cancers in adjacent regions such as the nasopharynx, oropharynx, larynx, and lung should be considered when dealing with patients with a history of heavy alcohol/tobacco consumption or previous oral cancer diagnosis.<sup>10</sup>

There are many treatment options for OL, both invasive and medical (topical and systemic). Invasive treatment options include conventional surgery, laser surgery (excision or evaporation), electrocoagulation and cryotherapy.<sup>11</sup>

## Methods

In our study, patients who applied to Ege University Facial and Mouth Lesions Council (EGEYA) between

2007 and 2015 and received clinical and histopathological diagnosis of oral leukoplakia were retrospectively reviewed through council data sheets and photo archives.

Patient data sheets and photo archives were scanned for background information regarding the sex and age of the patient, smoking/tobacco chewing habits, regular alcohol consumption, oral hygiene status and presence of amalgam fillings. Likewise, features such as the number and localization of OLs, clinical type of OL, histopathological examination results, treatment methods (smoking cessation, amalgam change, oral hygiene, surgery, cryotherapy, etc.), any mycological examination results, and field cancerization were evaluated.

The statistical analysis of the study was performed using IBM SPSS Statistics 21.0 package program. (IBM SPSS Statistics for Windows, Version 21.0. Armonk, NY: IBM Corp.)

## Results

Of the 79 patients, 40 were male (50.6%) and 39 (49.4%) were female. Patients were aged between 18-91, with a mean overall age of  $58.73 \pm 17.96$  years. Mean age of male patients were  $52.98 \pm 18.74$ , while the mean age of female patients were  $64.64 \pm 15.18$ .

Evaluation of the risk factors revealed that 45 patients (56.9%) were smokers (35.6% of the female patients and 64.4% of males). The amount of cigarettes ranged from 1-180 packs/year and the average was 28.44 packs per year. A tobacco-chewing habit was recorded in 3 patients (3.8%) while alcohol was regularly consumed by 22 patients (27.8%), all of whom were male. Thus, regular alcohol usage was a risk factor in 55% of males. Concomitant smoking and alcohol use, often considered to be the most important risk factor for OL, was recorded for 21 patients (26.5%). Oral hygiene was evaluated subjectively. Oral hygiene was found to be compromised in 54 patients (68.4%), while 28 patients had amalgam fillings (35.4%). Mycological examination was required in 22 (27.9%) patients and *Candida albicans* was detected in 15 (19%) of them. Suitable local or systemic antifungal therapy

**Table 1.** Distribution of risk factors according to gender

	Female	Male	Total number (n)	Total rate (%)
Smoking	16	29	45	57
Tobacco chewing	0	3	3	3.8
Regular alcohol use	0	22	22	27.8
Smoking+Alcohol use	0	21	21	26.5
Oral hygiene disorder	24	30	54	68.4
Amalgam fillings	15	13	28	35.4
Presence of <i>C.albicans</i>	11	4	15	19

was given to these patients (Table 1).

A total of 87 OL lesions were noted; with 1 OL in 72 patients (91.1%) 2 OL in 6 patients (7.5%), and 3 OL in 1 patient (1.2%). However, the total of OL lesions evaluated in our study was only 79 since only histopathologically examined lesions were included and only one histopathological sampling was performed on patients with multiple lesions.

Examination of the distribution pattern showed that most lesions were located in the buccal mucosa (30 lesions: 34.4%). The second most common location with 25 (28.7%) lesions was the tongue. Following this, there were 11 lesions (12.6%) in the gingiva, 6

lesions (6.8%) in the hard palate, 7 lesions (8%) in the soft palate, 5 lesions (5.7%) in the floor of the mouth and 3 lesions (3.4%) in the labial mucosa (Table 2).

Homogenous OL was seen in 39 patients (49.4%) and nonhomogeneous OL in 40 patients (50.6%). Of the 39 homogeneous OLs, 28 (35.4%) were thick-fissured and 11 (13.9%) were flat-thin. Of the 40 patients with nonhomogenous OL, 18 (22.8%) had granular nodules, 9 (11.4%) had verrucous, 8 (10.1%) had erythroleukoplakia and 5 (6.3%) had proliferative verrucous OL type (Table 3).

Biopsies were taken from the lesions of all patients included in the study and histological evaluation was

**Table 2.** Frequency of all OLs and oral mucosa localization

Localization	Total number (n)	Total rate (%)
Buccal mucosa	30	34.4
Tongue	25	28.7
Gingiva	11	12.6
Hard palate	6	6.8
Soft palate	7	8
Floor of the mouth	5	5.7
Labial mucosa	3	3.4

performed. As a result of this evaluation, 37 (46.8%) cases of squamous hyperplasia (SH) and hyperkeratosis, 12 (15.1%) cases of squamous intraepithelial neoplasia 1 (SIN1), 17 (21.5%) cases of SIN2, and 9 (11.3%) cases of SIN3 carcinoma in situ (CIS) were detected. In addition, there were 3 (3.7%) cases of squamous hyperplasia + SIN1, and 1 patient (1.1%) with both SIN2 + SIN3 (Table 4).

The treatment methods used for the 79 patients in the study were as follows: 38 (48.1%) underwent conventional surgical treatment, 11 (13.9%) had medical treatment and cryotherapy was used for 7 (8.9%). Smoking cessation was employed in 5 (6.3%) patients, amalgam

exchange in 5 (6.3%), oral hygiene in 3 (3.8%) patients and 'watch and wait' method in 3 (3.8%). In 7 patients (9.2%), multiple methods were administered concurrently (Table 5).

Field cancerization was detected in 6 of the 79 patients (7.5%) during follow-up: three female (3.7%) and 3 male (3.7%). They were aged between 42-77 years, with a mean of 64.1 years. 4 of these patients (5%) had no known risk factors, while the remaining 2 patients were known to have smoking and alcohol habits and one of the two also chewed tobacco. The distribution pattern of the OL lesions in these 6 patients comprised 3 (3.7%) in the buccal mucosa, 1 (1.2%) in the gingiva,

**Table 3.** Frequency of clinical type

		Total number (n)	Total rate (%)
<b>Homogenous OL</b>	Thin-smooth	11	13.9
	Thick-fissured	28	35.4
<b>Non-homogenous OL</b>	Granular nodules	18	22.8
	Verrucous	9	11.4
	Erythroleukoplakia	8	10.1
	Proliferative verrucous	5	6.3

**Table 4.** Distribution of histopathological diagnosis

Histopathological diagnosis	Total number (n)	Total rate (%)
Squamous hyperplasia + Hyperkeratosis	37	46.8
SIN 1	12	15.1
SIN 2	17	21.5
SIN 3	9	11.3
Squamous hyperplasia+ SIN 1	3	3.7
SIN 2 + SIN 3	1	1.1

SIN, squamous intraepithelial neoplasia

1 (1.2%) in the soft palate, and 1 (1.2%) in the floor of the mouth. 3 (3.7%) patients had homogeneous and 3 (3.7%) had nonhomogenous OL. These types were further classified as homogenous: 2 thin-straight (2.5%), 1 thick-fissured (1.2%); nonhomogenous: 1 erythroleukoplakia (1.2%), 1 granular nodular (1.2%), 1 proliferative verrucous (1.2%). Histopathological examination of these lesions revealed 3 patients with squamous hyperplasia and hyperkeratosis (3.7%), 2

with SIN3 (2.5%) and 1 with SIN2 (1.2%). 4 (5.2%) of the 6 patients (7.8%) had carcinoma of the tongue, 1 (1.3%) had lung carcinoma, and the one remaining patient (1.3%) was diagnosed with tonsil CIS, Squamous cell carcinoma (SCC) in the hypopharynx and epiglottis, and CIS of the larynx (Table 6).

### Discussion

Oral leukoplakia was defined by Van der Waal et al.,

**Table 5.** Distribution of applied treatment methods

Applied treatment methods	Total number (n)	Total rate (%)
Conventional surgical treatment	38	48.1
Medical treatment	11	13.9
Cryotherapy	7	8.9
Smoking cessation	5	6.3
Amalgam exchange	5	6.3
Provision of oral hygiene	3	3.8
“Watch and wait” method	3	3.8

as a predominantly white lesion or plaque with suspicious behavior that can be diagnosed after clinical and histopathological exclusion of other identifiable white diseases and disorders.<sup>12</sup>

Although OL was originally thought to be more prevalent in men because of tobacco consumption, in recent years, the disparity between OL rates in men and women has diminished.<sup>5</sup> In their study, Starzynska et al., screened 55911 patients from between 1999 and 2009, finding 204 OL patients for epidemiological and clinical analysis; they ascertained a male population of 49% (n=100) and female population of 51% (n=104).<sup>13</sup> In another study carried out by Liu et al., of 218 patients, 50.5% (n=110) patients were male and 49.5% (n=108) were female.<sup>14</sup> Our study consisted of 50.6% male (n=40) and 49.4% female patients (n=39).

In the study of Starzynska et al., 63% of patients were between the ages of 50-70. The mean age of the cohort was 58.1 years; female mean age was 59.4 years, male mean age was 56.7 years.<sup>13</sup> Liu et al., reported patients between 21-84 years of age with a mean age of 52.7 ± 11.20 years.<sup>14</sup> Holmstrup and colleagues also evaluated 269 lesions in 236 patients. Their patients were aged 23-92 years with a mean age of 60.8 years.<sup>11</sup> The ages of our 79 patients were between 18-91 years and their mean age was 58.73 ± 17.96. The mean age was 52.98 ± 18.74 in males and 64.64 ± 15.12 in females. In most studies, including our own, the mean patient age is between 50 and 60 years.

In our study, etiological factors such as smoking, tobacco chewing, alcohol consumption, oral hygiene disorder, presence of amalgam fillings and accompanying

candidiasis were evaluated. However, HPV, which is considered an important risk factor, could not be included in our retrospective study due to absence of data.

In a study by Bisht et al., 48 (53.3%) patients were non-smokers, 30 (33.3%) of the 90 OL patients smoked fewer than 10 cigarettes per day, while 12 (13.33%) patients smoked over 10 cigarettes per day.<sup>15</sup> Of the 204 OL patients who participated in the study conducted by Starzynska et al., 103 (50.49%) were smokers. 59 patients (28.92%) were female and 44 (21.57%) were male. The smoking rate was 88.88% in OL patients younger than 40 years.<sup>13</sup> Holmstrup et al., evaluated a total of 269 OL lesions in 236 patients, and 73% of these lesions were associated with smoking.<sup>11</sup> In our study, 56.9% (n=45) of the patients were smokers. Sixteen patients (20.2%) were female and 29 (36.7%) were male. The mean rate of smoking was 28.44 ±

34.63 packs per year. Therefore, in accordance with the literature, smoking was one of the most important risk factors found in our study.

In a study reported by Bisht et al., from India, 26 of the 90 OL patients (18.9%) chewed tobacco.<sup>15</sup> In our study, 3 male patients (3.8%) had a tobacco chewing habit.

In the study of Starzynska et al., 40.49% (n=83) of patients drank alcohol.<sup>13</sup> Liu et al., evaluated 218 patients with OL, and found 15 (6.9%) of the patients used alcohol on a regular basis, while 10 (4.6%) had given up alcohol.<sup>14</sup> In the study by Lee and friends, 370 (40.7%) of 1046 OL patients were alcohol users.<sup>16</sup> In our study, regular alcohol consumption was present in 22 patients (27.8%), while concurrent cigarette smoking and alcohol use were confirmed in 21 patients (26.5%). In the literature, alcohol consumption rates in OL patients vary and our study results are av-

**Table 6.** Characteristics of cases displaying field cancerization

Patient no	Age, gender	Risk factors	OL localization	OL clinical type	OL histopathology	Field cancerization
3	42, M	None	Tongue	Granular nodular	SIN2	Tongue SCC
5	72, F	None	Tongue	Thin straight	Squamous hyperplasia+ hyperkeratosis	Tongue SCC
8	52, F	None	Tongue	Thin straight	Squamous hyperplasia+ hyperkeratosis	Tongue SCC
39	70, F	None	Gingiva	Erythroleukoplakia	SIN3	Tongue SCC
41	77, M	Smoking, alcohol	Soft palate	Proliferative verrucous	SIN3	Tonsil CIS, Hypopharynx / epiglottis SCC, Larynx CIS
67	72, M	Smoking, Tobacco chewing, Alcohol	Floor of mouth	Thick fissured	Squamous hyperplasia+ hyperkeratosis	Lung carcinoma

CIS, carcinoma in situ ; SCC, Squamous cell carcinoma ; SIN, squamous intraepithelial neoplasia

erage values according to the literature.

In the study of Starzynska et al., 20.09% (n=41) of the patients had dental prosthesis; 8.33% (n=17) of these patients were male and 11.76% (n=24) were female. In the same study, the frequency of chronic mechanical trauma such as from amalgam fillings was 28.93% (n=59).<sup>13</sup> As in the literature, we agree that mechanical trauma caused by amalgam fillings may be a risk factor. In our patient group, the presence of amalgam fillings was as high as 28 patients (35.4%).

It is debatable whether *Candida albicans* is a risk factor for OL, or simply a superinfection over a pre-existing lesion.<sup>17</sup> Considering that some types of candida may cause nonhomogenous OL-like lesions, it is argued that lesions that do not respond to antifungal therapy should be considered as oral leukoplakia and should be approached accordingly.<sup>18</sup> The *Candida* species of fungal infections, especially *Candida albicans*, often accompany OL lesions.<sup>19</sup> In their study evaluating the relationship between candida colonization and OL, Sarkar et al. compared 40 OL patients with 21 control patients. On direct examination, *Candida albicans* was found in 47.5% of OL patients but only 14.3% of the control group. In the subsequent mycological culture, 64.9% of non-homogenous OL patients and 45% of all OL patients were positive for *Candida albicans* and the results were statistically significant.<sup>20</sup> In our study, mycological examination was performed on 22 patients (27.9%) and *Candida albicans* was detected in 15 (19%). Of these, 11 (13.9%) were female and 4 (5%) were male.

In a study evaluating the location of lesions in 1046 OL patients, Lee and colleagues obtained similar results to our study. Their distribution comprised lesions in the buccal mucosa in 660 patients (63%), on the tongue in 253 (24.1%), in the gingiva in 53 (5%), in the labial mucosa in 40 (3.8%), on the soft palate in 22 (2.1%), on the hard palate in 10 (0.95%) and at the floor of the mouth in 8 patients (0.76%).<sup>16</sup> Additionally, in the study of Chandran, of the 95 patients, 18.9% (n=18) of the OL lesions were located in the buccal mucosa, 17.9% (n=17) in the gingival, 26.3% (n=25)

in the floor of the mouth, 18.9% (n=18) on the tongue, 7.5% (n=6) in the soft palate, 3.2% (n=3) in the hard palate and 4.3% (n=4) settled in the labial mucosa.<sup>21</sup> Similar to the literature, the most common location in our study was the buccal mucosa.

The location and number of lesions in leukoplakia are significant for close follow-up because of the higher risk of malignancy in certain localizations, such as the tongue and floor of the mouth. In our study, we found a single lesion in 72 patients (91.1%), 2 lesions (7.5%) in 6 patients and 3 (1.2%) in 1 patient, making a total of 87 lesions. The most common site was buccal mucosa with a rate of 31.6% (n=25). The tongue area was second with 29.1% (n=23). Subsequent frequencies were 11.4% (n=9) in the gingiva, 7.6% (n=6) in the hard palate, 6.3% (n=5) in the soft palate, 6.3% (n=5) in the floor of the mouth and 2.5% (n=2) in labial mucosa.

Non-homogenous leukoplakias are known to carry more risk than homogenous leukoplakia. In the literature, Chandran and his colleagues evaluated 95 patients with OL, finding 85.3% of patients (n=81) with homogenous OL, 7.4% (n=7) with erythroleuplakia, 5.3% (n=5) verrucous, and 2.1% (n=2) proliferative verrucous OL.<sup>21</sup> In the study conducted by Starzynska et al., 204 patients had a total of 320 OL lesions. Homogenous OL was seen in 147 patients (72.05%) and non-homogenous in 57 patients (29.95%). 85 of the patients (41.7%) had unifocal OL and 119 (58.3%) had multifocal OL.<sup>13</sup> In our study, 39 (49.4%) patients had a homogenous type of OL, while 40 (50.6%) had a non-homogeneous type. Of the 39 homogeneous OLs, 28 (35.4%) were thick-fissured OL and 11 (13.9%) were thin-straight. Of the 40 patients with non-homogenous OL, 18 (22.8%) had granular nodules, 9 (11.4%) were verrucous, 8 (10.1%) were erythroleukoplakia and 5 (6.3%) were proliferative verrucous OL type.

When we look at the literature, in a study by Starzynska et al., histopathological evaluation of OLs revealed squamous hyperplasia in 60% of cases (n=192), SIN1 in 29.7% (n=95), and SIN2 in 10% (n=32), while 0.3% (n=1) resulted in SIN3.<sup>13</sup> In the study by Bisht et al.,



49 patients (54.4%) had mild dysplasia, 29 patients (32.2%) had moderate dysplasia, 9 patients (10%) had severe dysplasia and 3 patients (3.3%) had CIS.<sup>15</sup>

In our study, the histopathological examination of 79 OL lesions revealed squamous hyperplasia (SH) and hyperkeratosis in 37 (46.8%) patients, SIN1 in 12 patients (15.2%), SIN2 in 17 patients (21.5%), SIN3/CIS in 12 patients (15.1%), squamous hyperplasia + SIN1 in 3 patients (3.9%), and both SIN2 + SIN3 in 1 patient (1.3%). In our study, despite somewhat different ratios, the most frequent histopathologic response was squamous hyperplasia, as in the literature.

In addition, in the study by Holmstrup and colleagues, 94 lesions in 89 patients were treated surgically. Of the lesions treated surgically, 49% were non-homogenous, 9% were erythroleukoplakia and 41% were homogenous OL lesions. Meanwhile, a total of 175 lesions in 45 patients were treated non-operatively. 85% of the lesions treated with non-surgical methods were homogenous OL, while 11% were non-homogenous OLs and 3% were erythroleukoplakia.<sup>11</sup>

In our study, 38 patients (48.1%) received conventional surgical treatment, 11 (13.9%) had medical treatment, 7 (8.9%) had cryotherapy; smoking was stopped in 5 patients (8%), amalgams were changed in 5 (6.3%), oral hygiene was improved in 3 (3.8%) and 'watch and wait' method was applied in 3 cases (3.8%). In 7 patients (9.2%), multiple options were administered concurrently. In 2 (2.6%) of these patients, smoking cessation and oral hygiene with provided, while 2 (2.6%) underwent smoking cessation and medical treatment, 1(1.3%) had cryotherapy as well as cessation of smoking, 1 patient (1.3%) underwent smoking cessation, amalgam replacement and oral hygiene and in 1 case (1.3%) amalgam exchange, oral hygiene change and medical treatment were applied. In our study, as in the literature, surgical treatment is preferred in lesions with high risk of malignant transformation such as non-homogenous OL.

Although there are many treatment options for oral leukoplakia, there are no randomized controlled studies on treatment efficacy. The lack of standardization

of treatment methods is also an important problem. Over a one-year period, the rate of malignant transformation for untreated OL lesions is 2-3%. This risk is higher for erythroleukoplakia, erythroplakia and proliferative verrucous leukoplakia. Clearly, the main target in all treatment options is to reduce this rate, but even when current surgical approaches are applied, if risk factors persist, then the likelihood of leukoplakia developing in other regions due to field cancerization remains.<sup>13</sup> In our study, 6 patients (7.5%) with leukoplakia had additional field cancerization. 1 (1.2%) of these patients had smoking and alcohol habits, and 1 (1.2%) had habits of cigarette smoking, alcohol consumption and tobacco chewing, while 4 patients (5.2%) had no known risk factors. 4 (5.2%) of the 6 patients (7,8%) with field cancerization had tongue carcinoma, 1 (1.2%) had lung carcinoma, while 1 (1.2%) had tonsil and larynx CIS, hypopharynx and epiglottis SHK. In our study, no significant statistical relationship was found between field cancerization and risk factors such as localization, clinical type or the histopathological features of OL. However, we would like to emphasize that the presence of leukoplakia may be a significant finding in terms of field cancerization.

In conclusion, to minimize the risk of malignant transformation in leukoplakia lesions, the elimination of risk factors and early biopsy are essential. In patients whose histopathological examination reveals dysplasia or malignancy, regular follow-up and a multidisciplinary approach related to field cancerization are of vital importance in patients with oral leukoplakia.

## References

1. Brouns ER, Baart JA, Bloemena E, Karagozoglu H, van der Waal I. The relevance of uniform reporting in oral leukoplakia: definition, certainty factor and staging based on experience with 275 patients. *Med Oral Patol Oral Cir Bucal* 2013;18:19-26.
2. Petti S. Pooled estimate of world leukoplakia prevalence: a systematic review. *Oral Oncology* 2003;39:770-80.
3. Parlatescu I, Gheorghe C, Coculescu E, Tovar S. Oral leukoplakia - an update. *Maedica (Buchar)* 2014;9:88-93.

4. Einhorn J, Wersall J. Incidence of oral carcinoma in patients with leukoplakia of the oral mucosa. *Cancer* 1967;20:2189-93.
5. Riedler L. 'Bowenoid' leukoplaki in the anal region. *Klin Wochenschr* 1988;66:271-3.
6. Morton TH, Cabay RJ, Epstein JB. Proliferative verrucous leukoplakia and its progression to oral carcinoma: report of three cases. *J Oral Pathol Med* 2007;36:315-8.
7. van der Waal I. Potentially malignant disorders of the oral and oropharyngeal mucosa; terminology, classification and present concepts of management. *Oral Oncol* 2009;45:317-23.
8. Özbayrak S. *Ağız Hastalıkları Atlası*. İstanbul: Quintessence Yayıncılık Ltd. Şti, 2003.
9. Neville B.W., Damn D.D., Allen C.M., Bouquot J.E.: *Oral & Maxillofacial Pathology*. Saunders, Philadelphia 2002.
10. Axéll T, Pinborg J J, Smith C J, van der Waal I. Oral white lesions with special reference to precancerous and tobacco-related lesions: conclusions of an international symposium held in Uppsala, Sweden, May 18-21 1994. International Collaborative Group on Oral White Lesions. *Oral Pathol Med* 1994;25:49-54.
11. Holmstrup P, Vedtofte P, Reibel J, Stoltze K. Long-term treatment outcome of oral premalignant lesions. *Oral Oncology* 2006;42:461-74.
12. Bánóczy J, Squier C A, Kremer M, et al. The permeability of oral leukoplakia. *Eur J Oral Sci*, 2003;111:312-5.
13. Starzynska A, Pawlowska A, Renkielska D, Michajlowski I, Sobjanek M, Blazewicz I. Oral premalignant lesions: epidemiological and clinical analysis in the northern Polish population. *Postepy Dermatol Alergol* 2014;31:341-50.
14. Liu W, Wang YF, Zhou HW, Shi P, Zhou ZT, Tang GY. Malignant transformation of oral leukoplakia: a retrospective cohort study of 218 Chinese patients. *BMC Cancer* 2010;10:685.
15. Bisht RS, Singh AK, Sikarwar V, Darbari A. Study over the clinical picture and histopathology of leukoplakia and to establish the correlation between causative factors in the patients of Garhwal hill region. *Natl J Maxillofac Surg* 2013;4:177-80.
16. Lee JJ, Hung HC, Cheng SJ, et al. Carcinoma and dysplasia in oral leukoplakias in Taiwan: prevalence and risk factors. *Oral Surg Oral Med Oral Pathol Oral Radiol Endod* 2006;101:472-80.
17. Bouquot J E, Whitaker S B. Oral Leukoplakia -Rationale for diagnosis and prognosis of its clinical subtypes or 'phases'. *Quintessence Int* 1994;25:133-40.
18. Sciubba JJ: Oral leukoplakia. *Crit Rev Oral Biol Med* 1995;6:147-60.
19. Dilhari A, Weerasekera MM, Siriwardhana A, et al. Candida infection in oral leukoplakia: an unperceived public health problem. *Acta Odontol Scand* 2016;74:565-9.
20. Sarkar R, Rathod GP. Clinicopathologic assessment of Candida colonization of oral leukoplakia. *Indian J Dermatol Venereol Leprol* 2014; 80:413-8.
21. Chandran R, Meer S, Feller L. Oral leukoplakia in a South African sample: a clinicopathological study. *Oral Dis* 2013;19:592-7.