

The Comparative Analysis of Cone Beam Computed Tomography and Orthopantomography in the Radiological Evaluation of Spontaneous Bone Regeneration in Jaw Cysts After Enucleation

Kist Enükleasyonu Sonrası Oluşan Kemik Rejenerasyonunun Radyolojik Değerlendirmesinde Konik Işınlı Bilgisayarlı Tomografi ile Panoramik Radyografinin Karşılaştırmalı Olarak İncelenmesi

Yasin Çağlar Koşar, Nesrin Saruhan, Ömür Dereci

Eskişehir Osmangazi University, Faculty of Dentistry, Department of Oral and Maxillofacial Surgery, Eskişehir, Turkey

ORCID

Yasin Çağlar Koşar <https://orcid.org/0000-0002-7673-0347>

Nesrin Saruhan <https://orcid.org/0000-0003-1160-4179>

Ömür Dereci <https://orcid.org/0000-0001-2345-6789>

Yazışma Adresi / Correspondence:

Associate Prof. Dr. Ömür Dereci

Eskişehir Osmangazi University, Faculty of Dentistry Department of Oral and Maxillofacial Surgery, Meşelik Campus, 26480, Eskişehir

Tel: +90 505 772 09 50 E-mail: odereci@ogu.edu.tr

Geliş Tarihi / Received : 11-11-2018

Kabul Tarihi / Accepted : 22-11-2019

Yayın Tarihi / Online Published: 27-12-2019

Koşar Y.Ç., Saruhan N., Dereci Ö., The Comparative Analysis of Cone Beam Computed Tomography and Orthopantomography in the Radiological Evaluation of Spontaneous Bone Regeneration in Jaw Cysts After Enucleation, J Biotechnol and Strategic Health Res. 2019;3(3):203-207 DOI:10.34084/bshr.645263

Abstract

- Objective** The aim of this study is to compare the panoramic radiography and cone-beam computed tomography (CBCT) in the evaluation of bone healing after the enucleation of odontogenic cysts.
- Materials and Methods** Pre-operative and post-operative clinical and radiological data of patients who were successfully treated with enucleation between 01/01/2013 and 01/03/2017 with 1-year follow-up were retrieved from the archives and evaluated retrospectively. The panoramic radiographs and CBCT sections were transferred into a computer program and pre-operative and post-operative measurements were performed on the computer program. The manual segmentation method was used in the volume measurement in CBCT sections. An area index was calculated by multiplying the highest vertical and widest horizontal dimension of the cystic lesion on the panoramic radiography.
- Results** Twelve patients included in the study. Eight patients were male and 4 of them were female. The mean age was 45. The volume of the defect at post-operative 1-year control decreased by 83.05% on average. The area measurement showed a decrease of 38.79% at postoperative 1-year control. The volume of the cystic cavities in tomographic sections and cystic area on panoramic radiographs were significantly reduced at the end of 1-year follow-up ($p<0.05$). There was a significant and moderate positive relationship between the post-operative measurement values of CBCT and OPG ($p=0.021$, $r=0.655$).
- Conclusion** Panoramic radiography can be used as effective as CBCT to monitor spontaneous bone regeneration after the enucleation of jaw cysts.
- Keywords** Cone beam computed tomography, bone defect, odontogenic cyst, panoramic radiography

Özet

- Amaç** Bu çalışmanın amacı odontojenik kistlerin enükleasyonundan sonra oluşan kemik defektindeki iyileşmenin radyografik incelemesinde panoramik radyografi ve konik ışınli bilgisayarlı tomografiyi (KIBT) karşılaştırmaktır.
- Materyal ve Metod** 01/01/2013 ve 01/03/2017 tarihleri arasında başarılı bir şekilde cerrahi enükleasyon ile tedavi edilmiş ve 1 sene boyunca takip edilmiş hastaların klinik ve radyolojik verileri arşivlerden çıkarılıp incelenmiştir. Pre-operatif ve post-operatif alınmış panoramik radyografiler ve KIBT kesitleri bir bilgisayar programına aktarılarak ölçümler gerçekleştirildi. KIBT kesitlerinde defekt hacminin ölçümü için manüel segmentasyon metodu kullanıldı. Panoramik radyografilerde ise lezyonun sınırları dahilinde en geniş horizontal ve vertikal boyutu bir işaretçi yardımı ile ölçüldü. Horizontal ve vertikal ölçümler birbiri ile çarpılıp bir panoramik indeks elde edildi.
- Bulgular** On iki hasta çalışmaya dahil edildi. Sekiz hasta erkek, 4 hasta kadındı. Ortalama yaş 45 olarak hesaplandı. Post-operatif 1 yılda defektlerin hacmindeki azalma KIBT incelemesinde ortalama %83.05 ve ölçülen panoramik indeksteki azalma panoramik radyografi incelemesinde ortalama %38.79 olarak bulundu. KIBT ve Panoramik değerlendirmelerinde pre-operatif ve post-operatif ölçümler arasında istatistiksel olarak anlamlı fark bulundu ($p<0.05$). KIBT ve panoramik radyografi post-operatif ölçümleri arasında istatistiksel olarak anlamlı orta dereceli korelasyon tespit edildi ($p=0.021$, $r=0.655$).
- Sonuç** Panoramik radyografi kist enükleasyonu sonrası kemik iyileşmesini göstermede altın standart olan KIBT'ye benzer etkinlik göstermektedir.
- Anahtar Kelimeler** Kemik defekti, konik ışınli bilgisayarlı tomografi, odontojenik kist, panoramik radyografi

INTRODUCTION

One of the most common pathologies in the oral and maxillofacial region is cysts with or without dental origin.¹ Cysts in the jaws are classified as odontogenic and non-odontogenic according to their epithelial origin.² Odontogenic cysts are more common and originate from epithelial tissues forming dental structures while non-odontogenic cysts originate from epithelial cell residues.³ Clinical, radiological and histopathological examination is needed for the definitive diagnosis of odontogenic cysts in the jaws.

A variety of 2D imaging methods such as periapical radiographs, orthopantomography (OPG), and cephalometric radiographs are used for diagnosis of medical conditions in oral and maxillofacial surgery.⁴ However, several advanced imaging methods are needed when evaluating oral and maxillofacial pathologies in detail or before complex surgical operations. Cone-beam computed tomography (CBCT) is the preferred advanced imaging method in the radiological evaluation of maxillofacial hard structures today because it is cost-effective with high rendering quality and emits low levels of radiation compared to the Multislice Computed Tomography which is the basic tomography method that is used for many years in medicine.⁵

The aim of this study is to analyze the reduction in lesion size with the use of OPG and CBCT after surgical enucleation of odontogenic cysts and to compare these two imaging methods in the evaluation of spontaneous bone regeneration after odontogenic cyst enucleation.

Methods

Patient Selection

Ethics committee approval was obtained before the initiation of this study, which was planned as a retrospective clinical follow-up study on volunteer participants. (ESOGÜ Non-invasive Clinical Research Ethics Committee, Issue No: 80558721 / G-105) Pre-operative and post-operative clinical, histopathological and radiological data of patients

who were surgically enucleated and histopathologically diagnosed as odontogenic cyst between 01/01/2013-01/03/2017 were retrieved from archives and evaluated. The type and location of cysts were recorded. Inclusion criteria were designed as;

1. Patients whose pre-operative and post-operative panoramic radiographs and CBCT data are available in the archives without any damage.
2. Individuals with class I occlusal relationship.
3. Individuals older than 18 years
4. Patients with 1-year follow-up radiographs.

Radiographs and tomography data that was damaged or contained artifacts that prevented digital measurement and patients whose radiographic and clinical data are not available were not included in the study.

Radiographic Measurements

Panoramic images were obtained by a stationary orthopantomography device (Planmeca ProMax X-RAY UNIT, Helsinki, Finland) with d 90kV, 10mA, 1s parameters. Volumetric tomography images were obtained by using a volumetric tomography device (Planmeca ProMax 3D Mid X-RAY UNIT, Helsinki, Finland) with 90kV, 8mA, 13.5s parameters.

The volumetric tomography images obtained from the patients were transferred into a computer software (Synapse®, FujiFilm medical systems, USA) and measurements were performed under appropriate lighting on the computer screen. Volumetric measurements were made by the manual segmentation method with the computer software.⁶ Pre-operative (Figure 1-A, B) and post-operative (Figure 1-C, D) measurements were performed for all patients.

OPGs were examined by a single observer on the computer screen under the appropriate lighting using an imaging software (Planmeca Romexis Viewer 5.2.R, Helsinki, Finland). Measurements were made by marking the longest vertical distance drawn perpendicular to the cavity and

the widest horizontal distance drawn between the furthest horizontal lining of the cystic cavity. The obtained measurements were multiplied by each other to obtain a pre-operative (Figure 2-A) and post-operative (Figure 2-B) field index for each lesion.

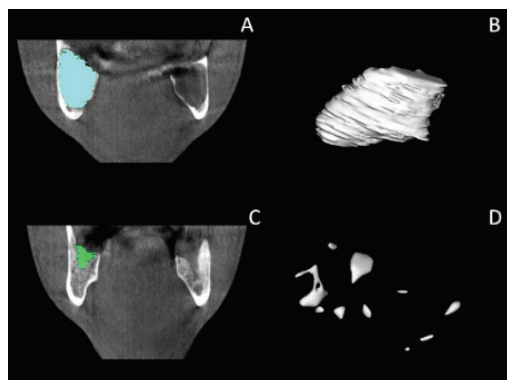


Figure 1. A- Cyst margins were marked in horizontal sections segment by segment pre-operatively and volume value measured with manual segmentation was shown in frontal section of CBCT image. B- The volume of mandibular cyst that was measured by manual segmentation was demonstrated in three dimension C- Same process was repeated at the end of 1 year follow-up period on frontal CBCT section. D- Three dimension reconstruction showed diminished volume of the mandibular cystic lesion.

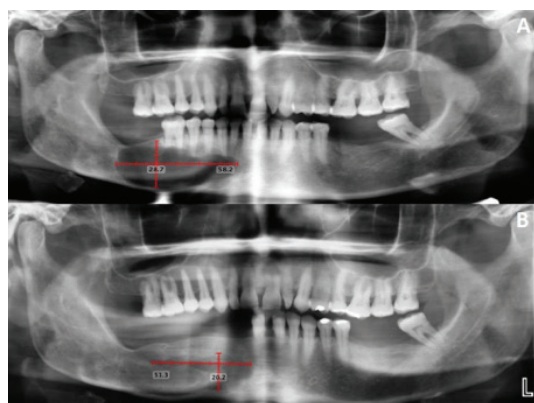


Figure 2. A- The longest mesio-distal and cranio-caudal distances of the mandibular cystic lesion were measured on panoramic radiography pre-operatively B- Post-operative panoramic radiography was taken at the end of 1 year follow-up period with same measurements.

In order to maximize the standardization and minimize error, the measurements were repeated 3 times at 15-day intervals and these measurements were averaged.

Statistical Analysis

Shapiro Wilks test was used to determine whether the data was normally distributed. Tests of changes over time of dependent samples that conform to normal distribution were analyzed by paired t-test. Pearson correlation coefficients were calculated for the variables to determine the direction and magnitude of the correlation between post-operative measurements evaluated with CBCT and OPG. IBM SPSS Statistics 21.0 (IBM SPSS Statistics for Windows, Version 21.0. Armonk, NY: IBM Corp.) was used for the analysis. $p < 0.05$ was accepted as statistically significant.

Results

Twelve patients were included in the study. The mean age of the patients was 45. Eight patients were male and 4 of them were female. Seven patients, 2 patients, and 3 patients were diagnosed as radicular cyst, residual cyst and odontogenic keratocyst, respectively. Volumetric tomography and panoramic radiography measurement values were shown in Tables 1 and 2. The mean pre-operative and post-operative volume values in CBCT evaluation were $4,463 \pm 3,514$ and 0.775 ± 0.422 ml, respectively. An average decrease of 83.05% was observed in the volumetric tomographic examination. Panoramic radiography pre-operative and post-operative field index measurements were found to be $758,445 \pm 519,727$ and $464,2183 \pm 409,623$ mm², respectively. An average decrease of 38.79% was observed in panoramic radiography measurements.

There were statistically significant differences between pre-operative and post-operative measurements in both CBCT and OPG evaluation of bone defects after the enucleation of jaw cysts ($p < 0.05$) (Table 3). A significant and moderate positive relationship between the post-operative measurement values of CBCT and OPG was observed

($p=0.021$, $r=0.655$).

Discussion

OPG is an easy and affordable method that is readily used in the evaluation of jaw cysts in the clinical setting of oral surgery. However, it is a uniplanar radiography that shows the anatomical structures in 2D dimension with several radiological disadvantages such as ghost images and superposition artifacts.^{5,7} In advanced oral and maxillary surgery, there is a need for detailed monitoring of jaw bone structures in order to analyze the extension of maxillofacial pathology or perform a delicate evaluation of bony structures for minor or major surgical operations.⁸ CBCT is the recommended radiological method in the evaluation of extensive and complicated jaw pathologies.⁹ Axial, coronal and sagittal CBCT sections provides a multiplanar view that facilitates better visualization of pathological borders of jaw lesions and the surgical approach to the cystic or tumoral pathology without any disruption to the anatomical structures.¹⁰

The most common treatment method for jaw cysts is enucleation with or without bone graft application in the residual cavity. Residual cystic cavity undergoes morphometric changes and spontaneous bone regeneration occurs in time even if the cavity is not filled with synthetic or allogenic bone grafts. Spontaneous bone regeneration occurs in post-surgical bone defects of jaw cysts regardless of the dimension of the cystic cavity.¹¹ Chiapasco et al.¹², reported that there was a reduction rate of 43.46% on the panoramic radiography in size of residual cystic cavities that were left for spontaneous regeneration after 1-year follow-up. Rubiu and Mombro¹⁴ reported an average bone defect reduction ratio of 88.47 % after cyst enucleation in their retrospective case series with 18 patients. Similarly, Chacko et al.¹⁴ reported that there was a size reduction of 81.03% in cystectomy defects of 44 consecutive patients. In the current study, the residual cystic cavities showed an average reduction of 38.79% in size and it is consistent with the literature findings

CBCT imaging was defined as a minimal invasive and conservative imaging method that provides precise pre-surgical planning in the evaluation of maxillofacial cystic pathologies.¹⁰ Deana et al.⁹ reported that CBCT is a very useful tool in surgical planning in cases of dentigerous cysts. On the other hand, Lim et al.¹⁵ reported that CBCT did not improve diagnostic accuracy when compared to panoramic radiography even it yields better visualization of pathological features. The prominent disadvantage of CBCT is the emittance of 3 to 7 times higher radiation dose compared to panoramic radiography.⁹ However, using the CBCT with basic principles of optimization and justification reduces the risk of high radiation-related complications.¹⁶ CBCT sections display borders and content of cystic lesions of the jaws very close to actual dimensions of the lesions with minimal error. This property makes the CBCT the golden standard to monitor the spontaneous regeneration in a cystic lesion after surgical enucleation. In the current study, a significant correlation between OPG and CBCT was found in the evaluation of the defect reduction in jaw cysts after surgery. This finding accounts for OPG usage in monitoring the spontaneous bone regeneration in residual cystic cavities shows similar results compared to the golden standard radiological technique of CBCT.

Panoramic radiography can be used as effective as CBCT to monitor spontaneous bone regeneration after the enucleation of jaw cysts. Despite the high imaging quality of CBCT, it is more appropriate to use it in limited and necessary cases because of the high radiation dose to which patients are exposed.

Source of Funding: None declared

Conflict of Interest: None declared

Kaynaklar

1. Jones A, Craig G, Franklin C. Range and demographics of odontogenic cysts diagnosed in a UK population over a 30 year period. *Journal of Oral Pathology Medicine (Baltimore)*. 2006; 35 :500-7.
2. Shear M, Speight P. *Classification and Frequency of Cysts of the Oral and Maxillofacial Tissues. Cysts of the Oral and Maxillofacial Regions. (4. Edition)*. John Wiley & Sons, New Jersey, 2008; p.1-123
3. Reichart P, Philipsen H. *Classification of Odontogenic Tumors and Allied Lesions. (1.Edition)*. Quintessence Publishing Co Ltd, London, 2000; p.1-90
4. Boeddinghaus R, Whyte A. *Current Concepts in Maxillofacial Imaging*. *Eur J Radiol*. 2008; 66: 396-418.
5. Suomalainen A, Esmaili EP, Robinson S. *Dentomaxillofacial imaging with panoramic views and cone beam CT. J Insights into imaging*. 2015; 6 :1-16.
6. Vallaeys K, Kacem A, Legoux H, et al. 3D dento-maxillary osteolytic lesion and active contour segmentation pilot study in CBCT: semi-automatic vs manual methods. *The British Institute of Radiology*. 2015; 44 :20150079.
7. Scarfe WC, Farman AG, Sukovic P. *Clinical applications of cone-beam computed tomography in dental practice*. *J Can Dent Assoc*. 2006; 72 :75-80.
8. Shin H, Nam K, Park H, et al. *Effective doses from panoramic radiography and CBCT (cone beam CT) using dose area product (DAP) in dentistry*. *Dentomaxillofac Radiol*. 2014; 43 :20130439.
9. Deana NF, Alves N. *Cone Beam CT in Diagnosis and Surgical Planning of Dentigerous Cyst*. *Case Rep Dent*. 2017; 2017: 7956041.
10. Prabhusankar K, Yuvaraj A, Prakash CA, et al. *CBCT Cyst Lesions Diagnosis Imaging Mandible Maxilla*. *J Clin Diagn Res*. 2014; 8: ZD03-5.
11. Hren NI, Miljavec M. *Spontaneous bone healing of the large bone defects in the mandible*. *Int J Oral Maxillofac Surg*. 2008; 37: 1111-16.
12. Chiapasco M, Rossi A, Motta JJ, et al. *Spontaneous bone regeneration after enucleation of large mandibular cysts: a radiographic computed analysis of 27 consecutive cases*. *J Oral Maxillofac Surg*. 2000; 58: 942-48.
13. Rubio ED, Mombriú CM. *Spontaneous Bone Healing after Cysts Enucleation without Bone Grafting Materials: A Randomized Clinical Study*. *Craniomaxillofac Trauma Reconstr*. 2015; 8(1): 14-22.
14. Chacko R, Kumar S, Paul A, et al. *Spontaneous Bone Regeneration After Enucleation of Large Jaw Cysts: A Digital Radiographic Analysis of 44 Consecutive Cases*. *J Clin Diagn Res*. 2015; 9: ZC84-9.
15. Lim LZ, Padilla RJ, Reside GJ, et al. *Comparing panoramic radiographs and cone beam computed tomography: Impact on radiographic features and differential diagnoses*. *Oral Surg Oral Med Oral Pathol Oral Radiol*. 2018; 126: 63-71.
16. Horner K. *"Cone-beam computed tomography for oral surgical applications: where is the evidence?" Oral Surgery*. 2013; 6 : 112-128.