

## Hepatoprotective Activity of Melatonin against Aluminium-Induced Toxicity and Oxidative Damage

Sevim TUNALI\*<sup>1</sup>  Nihal Omur KARABULUT BULAN<sup>2</sup>  Güner SARIKAYA UNAL<sup>2</sup>   
Refiye YANARDAG<sup>1</sup> 

<sup>1</sup> İstanbul Üniversitesi-Cerrahpaşa, Mühendislik Fakültesi, Kimya Bölümü, Avcılar, İstanbul/Türkiye

<sup>2</sup> İstanbul Üniversitesi, Fen Fakültesi, Biyoloji Bölümü, Vezneciler, İstanbul/Türkiye

(İlk Gönderim / Received: 10. 01. 2020, Kabul / Accepted: 20. 07.2020, Online Yayın / Published Online: 27. 07. 2020)

### Keywords:

Aluminium,  
biochemistry,  
histopathology,  
liver, melatonin,  
toxicity

**Abstract:** Aluminium (Al) is a nonessential metal that exists widely throughout the environment, and acute and chronic diseases are associated to it increased biological availability. Melatonin (Mel) has been shown to be an effective antioxidant with antitumor, anti-inflammatory, anti-excitatory, immunomodulatory, neuroprotective and vasomotor effects. The aim of the present study was to examine the effect of Al exposure on liver tissue, and the potential protective effects of Mel on the Al exposed liver tissue. Wistar albino rats utilised were grouped as follows; Group I: control group given normal saline intraperitoneally, group II: Mel control (injected 2% ethanol in normal saline subcutaneously), group III: rats injected 10 mg/kg Mel subcutaneously, group IV: rats administered 5 mg/kg Al<sub>2</sub>(SO<sub>4</sub>)<sub>3</sub> intraperitoneally, group V: rats concurrently injected both Al<sub>2</sub>(SO<sub>4</sub>)<sub>3</sub> and Mel. In the Al group, lipid peroxidation and protein carbonyl levels, myeloperoxidase, lactate dehydrogenase, thromboplastic activities, glucose-6-phosphate dehydrogenase activities increased, while liver glutathione level, superoxide dismutase, glutathione peroxidase and glutathione-S-transferase activities decreased. From histological analysis, the control rat tissues exhibited normal histological appearances. In the group given solely Al, degenerative changes such as picnotic nuclei, lymphoid infiltrate, hyperemia, necrotic areas, vacuolization and sinusoidal dilatations were observed. These effects were reversed upon Mel administration. These findings indicate that Mel is a likely useful agent against hepatotoxicity in Al induced liver damage.

## Alüminyum ile Oluşturulan Toksikite ve Oksidatif Hasara Karşı Melatoninin Hepatoprotektif Aktivitesi

### Anahtar Kelimeler:

Alüminyum,  
biyokimya,  
histopatoloji,  
melatonin,  
karaciğer,  
toksikite

**Özet:** Alüminyum (Al), doğada yaygın olarak bulunan esansiyel olmayan bir metaldir ve akut ve kronik hastalıklar bu elementin biyolojik olarak varlığına bağlı olarak artış göstermektedir. Melatoninin (Mel) antitümör, antiinflamatuvar, anti uyarıcı, immünomodülatör, nöroprotektif ve vazomotor etkileri olan etkili bir antioksidan madde olduğu gösterilmiştir. Bu çalışmanın amacı Al'nin karaciğer dokusu üzerindeki etkilerini ve Mel'in, Al verilen karaciğer dokusu üzerindeki potansiyel koruyucu etkilerini incelemektir. Çalışmada Wistar Albino ırkı sıçanlar beş gruba ayrılmıştır: Grup I: intraperitoneal olarak fizyolojik su çözeltisi verilen kontrol grubu, grup II: Mel kontrol (deri altına fizyolojik su çözeltisi içinde % 2 etanol enjekte edilen), grup III: subkutan 10 mg / kg Mel enjekte edilen sıçanlar, grup IV: intraperitoneal 5 mg / kg Al<sub>2</sub>(SO<sub>4</sub>)<sub>3</sub> verilen sıçanlar, grup V: hem Al<sub>2</sub>(SO<sub>4</sub>)<sub>3</sub> hem de Mel enjekte edilen sıçanlar. Al grubu verilen sıçanlarda lipit peroksidasyonu ve protein karbonil seviyeleri ile miyeloperoksidaz, laktat dehidrojenaz, tromboplastik aktivite ve glukoz-6-fosfat dehidrojenaz aktivitelerinde artış gözlenirken, karaciğer glutatyon seviyesi, süperoksit dismutaz, glutatyon peroksidaz ve glutatyon-S-transferaz aktivitelerinde azalma gözlemlendi. Histolojik analiz sonuçlarından kontrol grubu sıçan dokularının normal histolojik görünüm sergiledikleri gözlenmiştir. Sadece Al verilen grupta piknotik çekirdekler, lenfoid infiltrat, hiperemi, nekrotik alanlar, vakuolizasyon ve sinüzoidal dilatasyonlar gibi dejeneratif değişiklikler gözlenmiştir. Bu etkiler Mel uygulaması ile tersine çevrilmiştir. Elde edilen sonuçlar Mel'in Al kaynaklı karaciğer hasarında hepatotoksikiteye karşı muhtemel bir ajan olduğunu göstermektedir.

\*İlgiliyazar: stunali@istanbul.edu.tr

## 1. INTRODUCTION

Aluminium (Al) is widely found as oxide, fluoride or silicate in soil, water and air. It is the most widely used metals by humans. Its applicability cut across medicines (as antacids, tablet coating or as adjuvant), food processing, antiperspirants, additive in cosmetics among others (Esparza et al., 2019). In animal, the most common route of Al exposure is via food and water. The prominent sources of this element are corn, salt, yellow cheese, spices, tea, cosmetics, ware, herbs and containers. Al is reported to accumulate in all mammalian tissues such as liver, bones, brain, muscles, heart, erythrocytes, ovary, immune system and lungs. It has been shown that aluminium sulfate  $[(Al_2(SO_4)_3)]$  causes toxicity of the liver, kidneys and nervous system of laboratory animals (Schetinger et al., 1999; Gawish, 2005; Sun et al., 2015; Yu et al., 2019). Liver is the major organ responsible for metabolism, detoxification and secretory functions of the body. However, the ease of Al absorption by gastrointestinal tract result to its rapid accumulates in the liver cells and organelles. Gonzales et al. (2009) demonstrated that the accumulation of Al in liver results to harmful effects (González et al., 2009). More so, Al and its compounds may bind to DNA and RNA, distort enzyme activities and function of other biomolecules. In addition, Al has been implicated to precipitate oxidative via lipid peroxidation and increased generation of free radical (Reiter, 2000; Karabulut-Bulan et al., 2015;).

Antioxidants attenuate and prevent free radical induced lipid peroxidation and chain reaction. Melatonin (N-acetyl-5-methoxytryptamine; Mel) is a highly lipophilic small molecular size pineal gland hormone. It crosses biologic membranes easily and can reach all cellular compartments. Previous studies suggest that Mel function as an antioxidant and reduce oxidative damage *in vivo* (Reiter and Maestroni, 1999; Reiter, 2003). More so, several studies indicate that it attenuated tissue injury (Esparza, 2003; Farias, 2012).

The present study was aimed at investigating the protective effect of Mel against Al induced oxidative stress in rat liver, and to determine the possible use of Mel in alleviating Al induced damage, biochemically and histologically.

## 2. MATERIAL AND METHODS

### 2.1. Experimental Design

Forty adult male Wistar albino rats of 230-250 g were acquired from the Experimental Medical Research Institute of Istanbul University (DETAE). The Animal Care and Use Committee of Istanbul University reviewed and approved the experimental protocols (Ethical committee: 102/27.08.2009). All the rats were confirmed to be clinically healthy and allowed access to water and pelleted laboratory chow *ad libitum*.

Randomly, the animals were divided into five groups (n=8 per group). Group I: control animals that received physiological saline intraperitoneally; group II: Mel control group which were administered 2% ethanol in normal saline subcutaneously; group III: animals administered 10 mg/kg Mel subcutaneously; group IV: animals given 5 mg/kg  $Al_2(SO_4)_3$  intraperitoneally; group V: animals simultaneously dosed with  $Al_2(SO_4)_3$  and Mel (Salido, 2013). The dosages were administered to the animals three times per week for one month according to the protocol of our previous study Bulan et al., (2015). The animals were anaesthetised with ketamine hydrochloride (**Ketalar, Pfizer, Istanbul, Turkey**) after the experimental period, and liver tissues collected. All chemicals and reagents used in the experiment are of analytical grade.

### 2.2. Biochemical Assays

Liver samples collected were stored at -80 °C until needed for use. The frozen tissues were allowed to gradually defrost, followed by 10% (w/v) homogenization in ice-cold saline using a glass homogenizer. The homogenate was thereafter centrifuged at 10,000g for 20

min, and the clear supernatant was used for estimation of protein, glutathione (GSH), lipid peroxidation (LPO), protein carbonyl (PC) levels, in addition to enzyme activities. The liver tissue GSH, LPO and PC levels were determined according to the method of Beutler (1975), Ledwozyw et al. (1986) and Levine et al. (1990) respectively. Myeloperoxidase (MPO) was determined according to the method of Wei and Frenke (1991), lactate dehydrogenase (LDH) according to the method of Wroblewski (1957), tissue factor (TF) according to the Quick's one-stage method (Ingram and Hills M, 1976), glutathione peroxidase (GPx) according to the method of Paglia and Valentine (1967) and modified by Wendel (1981), glutathione-S-transferase (GST) according to the Habig and Jacoby (1981), glucose-6-phosphate dehydrogenase (G6PDH) according to the Betke et al. (1967) and superoxide dismutase (SOD) according to the Mylorie et al. (1981). Protein levels were assayed by the method of Lowry et al. (1957) using serum albumin as standard.

### 2.3. Histopathology

For light microscopic investigations, the collected liver samples were fixed in Bouin's fixative, followed by dehydration with alcohol, before being embedded in paraffin. Histopathological scoring was done following the staining of 5 µm section of liver tissue with haematoxylin and eosin (H&E). By examining five randomly selected areas at x400 magnification, the semi-quantitative histological assessment of liver damage was done using modified histological criteria described by Belaïd-Nouira et al. (2013). Using a scale 0 to 4 (0: none; 1: mild; 2: moderate; 3: severe and 4: very severe) for the criteria, liver injury was assessed based on disrupted arrangement of hepatocytes, sinusoidal dilatation, hyperemia, vacuolisation, lymphoid infiltrate, pyknotic nuclei, and disruption of the

hepatic cords. The observed sections were photographed with Olympus DP71 digital camera fitted to Olympus CX41 microscope.

### 2.3. Statistical Analysis

The data of this study are expressed as mean ± standard deviation (SD). Results from histological study were analysed by one-way analysis of variance (ANOVA) using GraphPad Prism 3.0 program (GraphPad Software, San Diego, CA, USA). Tukey's multiple comparisons test was used to determine difference between groups. The NCSS statistical package was employed for unpaired *t* test and analysis of variance of biochemical data. Significant differences considered/taken at  $p < 0.05$ .

## 3. RESULTS

### 3.1. Biochemical Results

The liver GSH, LPO and PC levels are presented in Table 1. Compared to the control group, the GSH level of A1 group decreased significantly ( $p < 0.005$ ). Administration of Mel to the A1 group reversed this effect, and brought about significant elevation GSH ( $p < 0.001$ ). More so, the tissue levels of LPO and PC were significantly elevated in A1 administered group in comparison to control ( $p < 0.05$ ,  $p < 0.05$ ). However, treatment with Mel resulted to statistically insignificant decrease of LPO, while PC levels were significantly decreased ( $p < 0.05$ ).

The MPO, LDH and TF activity of liver samples are given in Table 2. In comparison to the control group, a significantly higher activity of MPO and LDH was observed in the A1 administered group ( $p < 0.05$ ,  $p < 0.05$ ). The administration of Mel to the A1 group resulted to a significant decrease of both MPO and LDH activity ( $p < 0.05$ ,  $p < 0.0001$ ).

**Table 1.** Liver glutathione (GSH), lipid peroxidation (LPO) and protein carbonyl (PC) levels for all groups.

Groups	GSH (U/mg prot)*	LPO (U/mg prot)*	PC (nmol/mg prot)*
Control	7.92 ± 3.50	1.41 ± 0.80	0.12 ± 0.06
Control + Mel	4.68 ± 3.25	2.33 ± 1.04	0.11 ± 0.03
Mel	7.28 ± 1.89	2.54 ± 1.29	0.12 ± 0.11
Al	1.66 ± 0.93 <sup>a</sup>	2.54 ± 0.48 <sup>c</sup>	0.76 ± 0.15 <sup>c</sup>
Al + Mel	9.51 ± 1.48 <sup>b</sup>	2.05 ± 0.73	0.19 ± 0.11 <sup>d</sup>
P <sub>ANOVA</sub>	0.001	0.227	0.0001

\*Mean ± SD

<sup>a</sup>P < 0.005 versus control group<sup>b</sup>P < 0.001 versus Al group<sup>c</sup>P < 0.05 versus control group<sup>d</sup>P < 0.0001 versus Al group**Table 2.** Liver myeloperoxidase (MPO), lactate dehydrogenase (LDH) and tissue factors (TF) activities for all groups.

Groups	MPO (U/g tissue)*	LDH (U/mg prot)*	TF (sec)*
Control	1.09 ± 0.58	4.22 ± 1.84	199.00 ± 40.99
Control + Mel	2.87 ± 1.63	22.72 ± 31.27	234.15 ± 31.93
Mel	1.99 ± 0.44	11.90 ± 8.67	255.44 ± 51.00
Al	5.06 ± 2.00 <sup>a</sup>	13.89 ± 3.47 <sup>a</sup>	167.29 ± 29.49 <sup>a</sup>
Al + Mel	1.49 ± 0.31 <sup>b</sup>	7.53 ± 3.01 <sup>c</sup>	205.43 ± 27.39 <sup>b</sup>
P <sub>ANOVA</sub>	0.001	0.447	0.001

\*Mean ± SD

<sup>a</sup>P < 0.05 versus control group<sup>b</sup>P < 0.05 versus Al group<sup>c</sup>P < 0.0001 versus control group**Table 3.** Liver glucose-6-phosphate dehydrogenase (G6PDH), superoxide dismutase activities (SOD), glutathione peroxidase (GPx) and glutathione-S-transferase (GST) activities for all groups.

Groups	G6PDH (mU/mg prot)*	SOD (U/mg prot)*	GPx (U/mg prot)*
Control	17.19 ± 6.67	8.06 ± 2.49	17.95 ± 5.69
Control + Mel	26.34 ± 12.50	4.58 ± 2.77	17.14 ± 1.22
Mel	20.96 ± 9.00	4.74 ± 2.42	23.70 ± 11.14
Al	23.54 ± 4.16 <sup>a</sup>	3.20 ± 1.92 <sup>a</sup>	9.67 ± 2.45 <sup>a</sup>
Al + Mel	16.88 ± 0.89 <sup>b</sup>	13.91 ± 5.30 <sup>b</sup>	16.06 ± 3.88 <sup>b</sup>
P <sub>ANOVA</sub>	0.232	0.0001	0.080

\*Mean ± SD

<sup>a</sup>P < 0.05 versus control group<sup>b</sup>P < 0.05 versus Al group

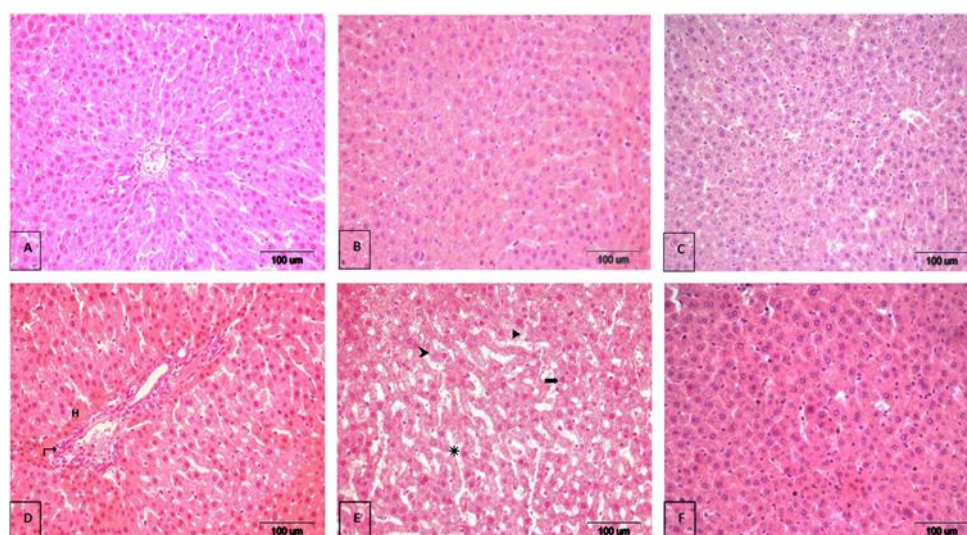
Furthermore, the significantly diminished TF activity of Al group ( $p < 0.05$ ) was restored in Al+Mel group to a level significantly higher than that of control animals ( $p < 0.05$ ).

The activities of G6PDH, SOD, GPx and GST are presented in Table 3. The administration of Al resulted to significantly elevated liver G6PDH activity ( $p < 0.05$ ), which was significantly decreased in the Mel treated Al group ( $p < 0.05$ ). On the other hand, significantly reduced SOD, GPx and GST activity in Al given group was observed compared to control ( $p < 0.05$ ). Nevertheless, Mel dosing significantly increased the activity of these enzymes ( $p < 0.05$ ).

### 3.2. Histopathological Results

Normal lobular architect and hepatocytes arranged in cords encircling the central canal, which is a depiction normal histology was observed in both control and Mel

control rats (Fig. 1A, 1B). The group injected solely Mel showed no histological variation from the control groups (Fig. 1C). In comparison to control groups, degenerative changes such as dilated and distorted sinusoids, pycnotic nuclei, lymphoid infiltrate, hyperemia, necrotic areas, moderate cytoplasmic vacuolization and disruption of the hepatic cords histo-architecture were observed in animals solely administered Al (Fig. 1D, 1E). Microscopic analysis of tissue sections from Al+Mel treated group demonstrated ameliorated effect of Mel on liver damage (Fig.1F). The Al administered group exhibited significantly higher histological damage scores when compared to control ( $P < 0.05$ ). Though the damage scores of the Al+Mel group were significantly lower than that of Al group ( $P < 0.01$ ) (Fig. 2), the scores of the Mel treated Al group (Group V) was still significantly higher than that of the control and Mel control group ( $P < 0.05$ ). This demonstrates that Mel has potentials in attenuating Al induced hepatotoxicity.



**Fig 1.** Normal histological appearance of the liver in control (A), control of melatonin (B) and melatonin (C) groups. The histological appearance of the liver of aluminium-administered group (D, E). Sinusoidal dilatations (\*), pycnotic nuclei (≡), vacuolization (▷), necrotic areas (▶), lymphoid infiltrate (↔), hyperemia (H). Histological appearance of the liver of rats given aluminium and melatonin (F). Hematoxylin-Eosin, Bar: 100  $\mu$ m.

#### 4. DISCUSSION

Al and Al salts accumulate in the liver following an intravenous or oral administration; this is despite being the main organ involved in the detoxification and excretion exogenous and endogenous xenobiotics (Spencer et al., 1995). Thus, Al is associated with toxicity leading to anaemia, impaired bone metabolism, neurologic defects, hepatic disease etc.

GSH is a non-enzymatic biological antioxidant in animals, whose reduced form essential for cleansing of toxic substances. The cellular damage and other detrimental effects caused by free radicals generated via reactivate oxygen species (ROS), peroxide or metal ions is prevented by this peptide. The decreased liver GSH levels observed in Al administered rats of this study is suggested to be consequence of GSH reserve depletion due to increased oxidative stress. Mel supplementation helped retain the levels of reduced GSH.

Among the critical manifestations of metal induced oxidative damage is the increase level of LPO. Al acts as a pro-oxidant and significantly hastens iron-mediated LPO (Exley et al., 2002 ). These result to distortion of structure and function DNA and primarily membrane proteins (Zatta et al., 2002). Thus, elevated LPO levels ultimately leads to altered cellular function (Bächli, 2000). In the present study, an elevation in TF activity attributed to inflamed hepatocytes membrane was observed in the Al group when compared to the control. But this effect was reversed upon treatment with Mel. Mel and its metabolites are reported to display anti-inflammatory effects (Ma et al., 2014). Therefore, reversal of TF activity by Mel in the Al group may be due to its anti-inflammatory potency. Yousef (2004) demonstrated that LPO in liver, kidney, brain and testes increased when Al was administered to rabbits. Similarly, Karabulut-Bulan et al. (2015) and Bulan et al. (2015) stated that LPO levels were amplified in small intestine and kidney of Al treated rats. These reports are in accordance with the findings of the present study which indicated a significantly increased

LPO in rats' liver. The administration of Mel curtailed these changes.

Among the primary targets of ROS are cellular proteins components. ROS precipitate the formation and accumulation of oxidized protein products which might exhibit impaired cellular function. The administration of Al in the present study triggered substantial increase of tissue PC levels. This is an indication that Al administration potentiates oxidative stress and PC generation in the liver. Conversely, Mel halted the progression of PC levels, and as well restored the normal functionality of hepatocytes. Since the PC level correlates with the severity of pathogenesis, the results of this work indicate that Mel may serve as an antidote to Al toxicity (Chevion et al., 2000).

Cell necrosis leads to a rise in concentration of the LDH enzyme in tissues such as liver, brain, kidney etc. It elevated activity suggests cellular leakage or loss of cell membranes functionality and integrity (Rajesh and Latha, 2004). Therefore, assessment of this enzyme serves as markers of hepatotoxicity induced by endogenous or exogenous toxicants. Some researcher reported that LDH activities were increased during Al treatment (Bulan et al., 2015). These reports are in agreement with the present finding, where administration of Al triggered a substantial upsurge in LDH activity. Mel treatment decreased the increased LDH activity in the Al group. Thereby, suggesting the protective effect of Mel in maintaining of hepatocyte functionality and membrane integrity.

Neutrophils are major effector cells found in vast inflammatory diseases, and they are also prospective sources of ROS. The azurophilic granule enzyme called MPO is principally found in polymorphonuclear leukocytes and is associated with inflammatory processes (Kettle and Winterbourn, 1997). From the finding of this study, it can be proposed that Al induced neutrophil-dependent oxidative damage to hepatocytes, since MPO activity was observed to increase. Conversely, Mel treatment

obstructed neutrophil proliferation, ameliorated the hepatocytes and decreased MPO activity.

The liver has a vital role in blood coagulation and haemostasis. Distortion of hepatocytes integrity is associated with distorted TF; a membrane glycoprotein that aid coagulation in damaged vessels and tissues. The increased TF levels are associated with lowered blood clotting time as well as tissue injury. Similar to the present finding, Al is reported to activate in mice liver (Hammad et al., 2013; Hacıhasanoglu and Yanardag, 2015).

NADPH is produced in the first step of HMP shunt from  $\text{NADP}^+$  by the action of G6PD, which is the regulatory enzyme of this pathway. The NADPH generated serves as a reducing equivalent in some anabolic reactions and as a donor of H atom in antioxidant defence system. In the present study, Al administration induced increased activity of liver G6PD. This indicates an increased generation of  $\text{NADPH} + \text{H}^+$  via HMP shunt, so as to mitigate excessive accumulation ROS and rather hasten detoxification processes. Studies by Bulan et al. (2015) showed that Al induced the elevation of intestinal tissue G6PD level. Similarly, Martins et al. (1986) reported an increased G6PD activity in brain of rats receiving Al dosage. Just like in the present study, the administration of Mel reversed this effect by tangibly diminishing G6PD activity of the Al administered group.

It is established that human have an established antioxidant system which mop up free radicals and ROS from the biological system. The antioxidant enzymes which are integral part of the antioxidant system play integral role in the detoxification of peroxides among other radicals. The results of this study are in agreement with earlier report showing decreased antioxidant enzyme activities subsequent to Al treated. In our previous study, a significant decrease of small intestinal CAT, SOD and  $\text{GP}_x$  activities in Al administered group was reported, but the administration of Mel prevented these changes (Bulan et al., 2015). Other studies also found that Mel dosing attenuated oxidative stress by increasing the

activity of antioxidant enzymes (Rajesh and Latha, 2004; Karabulut-Bulan, 2015).

Exposure to Al has been shown to primarily affect the liver of experimental animals and can possibility accumulate in the liver (Bogdanovic et al., 2008; Zhu et al., 2013). Its accumulation in the liver leads to cholestasis (Sinska, 2004). More so, prolonged intake/exposure is demonstrated to accelerate senescence in adult mice liver (Buraimoh, 2012). This is likely due to the ability of Al to disrupt hepatic cords and increase vacuolisation of the liver, thus altering histoarchitecture (Bhasin, 2014). Kutlubay et al. (2007) indicated that Al administration resulted in the dilatation and bleeding around sinusoids of liver, in addition to spaces and impaired radial arrangement of the hepatocytes of rats. These findings agree with the histopathological observations of the present study, in which dilated and distorted sinusoids, picnotic nuclei, lymphoid infiltrate, hyperemia, necrotic areas, moderate cytoplasmic vacuolisation and disruption of the hepatic cords were observed. The liver of rats simultaneously exposed to Al and vitamin E appeared to have normal histological structure (Kutlubay et al., 2007). Just like vitamin E, Mel which is small lipophilic molecule acting as an antioxidant in several oxidants related toxicological models (Li et al., 2008). In one study, Mel was shown to hinder Al induced oxidative alterations on the liver and kidney of intact and ovariectomized female rats (Contini et al., 2011). These findings were similar to our observations. As a result, we suggest that Mel is a potentially beneficial agent for reducing Al induced hepatotoxicity.

### **Declaration of Conflicting Interests**

The author(s) declared no potential conflicts of interest with respect to the research, authorship, and/or publication of this article.

**ACKNOWLEDGEMENTS**

This study was supported by the Scientific Research Projects Coordination Unit of Istanbul University (Project no: T-4148, UDP-33694).

**REFERENCES**

- Bächli E. (2000). History of tissue factor. *British Journal of Haematology*, 110, 248-55.
- Belaid Noura Y., Bakhta H., Haouas Z., Flehi-Slim I., Neffati F., Najjar M.F., Cheikh H.B. (2013). Fenugreek seeds, a hepatoprotector forage crop against chronic AlCl<sub>3</sub> toxicity. *BMC Veterinary Research*, 9, 22.
- Betke K., Brewer G.J., Krikman H.N., Luzzatto L., Motulsky A.C., Domingo G.J., Price R.N. (1967). Standardized method for G-6-PD assay of haemolysates. *World Health Organization Technical Report Series*, 366, 30-32.
- Beutler E. (1975). *Glutathione in red cell metabolism: a manual of biochemical methods*. 2nd ed. New York: Grune and Stratton, pp. 112-114.
- Bhasin P., Singla N., Dhawan D.K. (2014). Protective role of zinc during aluminum-induced hepatotoxicity. *Environmental Toxicology*, 29, 320-327.
- Bogdanovic M., Janeva A.B., Bulat P. (2008). Histopathological changes in rat liver after a single high dose of aluminium. *Archives of Industrial Hygiene and Toxicology*, 59, 97-101.
- Bulan N.Ö., Sarıkaya-Ünal G., Tunali S., Arda-Pirinççi P., Yanardağ R. (2015). Melatonin is a potent modulator of antioxidative defense and cellular proliferation against aluminum toxicity in rats. *Turkish Journal of Biology*, 39, 911-924.
- Buraimoh A.A., Ojo S.A., Hambolu J.O., Adebisi S.S. (2012). Effects of aluminium chloride exposure on the histology of the liver of adult wistar rat. *IOSR Journal of Pharmacy*, 3, 525-533.
- Chevion M., Berenshtein E., Stadtman E.R. (2000). Human studies related to protein oxidation: protein carbonyl content as a marker of damage. *Free Radical Research*, 33, s99-s108.
- Contini M.D., Millen N., Gonzalez M., Mahieu S. (2011). Melatonin prevents oxidative stress in ovariectomized rats treated with aluminium. *Biological Trace Element Research*, 144, 924-943.
- Esparza J.L., Gómez M., Domingo J.L. (2019). Role of melatonin in aluminum-related neurodegenerative disorders: a review. *Biological Trace Element Research*, 188, 60-67.
- Esparza J.L., Gomez M., Romeu M., Mulero M., Sanchez D.J., Mallol J., Domingo J.L. (2003). Aluminum-induced pro-oxidant effects in rats: protective role of exogenous melatonin. *Journal of Pineal Research*, 35, 32-39.
- Exley C. (2004). The pro-oxidant activity of aluminum. *Free Radical Biology & Medicine*, 36, 380-7.
- Farias J.G., Zepeda A.B., Calaf G.M. (2012). Melatonin protects the heart, lungs and kidneys from oxidative stress under intermittent hypobaric hypoxia in rats. *Biological Research*, 45, 81-85.
- González M.A., Bernal C.A., Mahieu S., Stella M., Carrillo M. (2009). The interactions between the chronic exposure to Aluminum and liver regeneration on bile flow and organic anion transport in rats. *Biological Trace Element Research*, 127, 164-76.



- Habig W., Jacoby W.B. (1981). Assays for differentiation of glutathione-S-transferases. *Methods in Enzymology*, 77, 398-405.
- Hacihasanoglu Cakmak N., Yanardağ R. (2015). Edaravone, a free radical scavenger, protects liver against valproic acid induced toxicity. *Journal of the Serbian Chemical Society*, 80, 627-637.
- Hammad M.A., Abdel-Bakky M.S., Walker L.A., Ashfag M.G. (2013). Tissue factor antisense deoxyoligonucleotide prevents monocrotaline/LPS hepatotoxicity in mice. *Journal of Applied Toxicology*, 33, 774-83.
- Ingram G.I.C., Hills M. (1976). Reference method for the one stage prothrombin time test on human blood. *Thrombosis and Haemostasis*, 36, 237-238.
- Karabulut-Bulan O., Bayrak B.B., Arda-Pirincci P., Sarikaya-Unal G., Us H. Yanardag R. (2015). Role of exogenous melatonin on cell proliferation and oxidant/antioxidant system in aluminum-induced renal toxicity. *Biological Trace Element Research*, 168, 141-9.
- Kettle A.J., Winterbourn C.C. (1997). Myeloperoxidase: a key regulator of neutrophil oxidant production. *Redox Report*, 3, 3-15.
- Kutlubay R., Oğuz E.O., Abban G., Turgut S. (2007). Amelioration of aluminium-induced liver damage by vitamin E. *Saudi Medical Journal*, 28, 197-200.
- Ledwozyw A., Michalak J., Stepień A., Kadziolka A. (1986). The relationship between plasma triglycerides, cholesterol, total lipids and lipid peroxidation products during human atherosclerosis. *Clinica Chimica Acta; International Journal of Clinical Chemistry*, 155, 275-84.
- Levine R.L., Garland D., Oliver C.N., Amici A., Climent I., Lenz A.G., Ahn B.W., Shaltiel S., Stadtman E.R. (1990). Determination of carbonyl content in oxidatively modified proteins. *Methods in Enzymology*, 186, 464-478.
- Li J.Y., Yin H.Z., Gu X., Zhou Y., Zhang W.H., Qin Y.M. (2008). Melatonin protects liver from intestine ischemia reperfusion injury in rats. *World Journal of Gastroenterology*, 14, 7392-7396.
- Lowry O.H., Rosebrough N.J., Farr A.L., Randall R.J. (1951). Protein measurement with the folin phenol reagent. *The Journal of Biological Chemistry*, 193, 265-275.
- Ma P., Yan B., Zeng Q., Liu X., Wu Y., Jiao M., Liu C., Wu C., Yang X. (2014). Oral exposure of Kunming mice to diisononyl phthalate induces hepatic and renal tissue injury through the accumulation of ROS. Protective effect of melatonin. *Food and Chemical Toxicology*, 68, 247-56.
- Martins R.N., Harper C.G., Stokes G.B., Masters C.L. (1986). Increased cerebral glucose-6-phosphate dehydrogenase activity in Alzheimer's disease may reflect oxidative stress. *Journal of Neurochemistry*, 46, 1042-1045.
- Myroie A.A., Collins H., Umbles C., Kyle J. (1981). Erythrocyte superoxide dismutase activity and other parameters of copper status in rats ingesting lead acetate. *Toxicology and Applied Pharmacology*, 82, 512-520.
- Pagla D.E., Valentine W.N. (1967). Studies on the quantitative and qualitative characterization of erythrocyte glutathione peroxidase. *The Journal of Laboratory and Clinical Medicine* 70: 158-169.
- Rajesh M.G., Latha M.S. (2004). Preliminary evaluation of the antihepatotoxic activity of Kamilari, a polyherbal formulation. *Journal of Ethnopharmacology*, 91, 99-104.
- Reiter R.J. (2000). Melatonin: lowering the high price of free radicals. *News in Physiological Sciences*, 15, 246-250.

- Reiter R.J., Maestroni G.J. (1999). Melatonin in relation to the antioxidative defense and immune systems: possible implications for cell and organ transplantation. *Journal of Molecular Medicine (Berlin, Germany)*, 77, 36-9.
- Reiter R.J., Tan D.X., Manchester L.C., Lopez-Burillo S., Sainz RM Mayo J.C. (2003). Melatonin: detoxification of oxygen and nitrogen-based toxic reactants. *Advances in Experimental Medicine and Biology*, 527, 539-48.
- Salido E.M., Bordone M., De Laurentiis A., Chianelli M., Keller Sermiento M.I., Dorfman D., Rosenstein R.E. (2013). Therapeutic efficacy of melatonin in reducing retinal damage in an experimental model of early type 2 diabetes in rats. *Journal of Pineal Research*, 54, 179-189.
- Schetinger M.R.C, Bonan C.D., Morsch V.M., Bohrer D., Valentim L.M., Rodrigues S.R. (1999). Effects of aluminum sulfate on delta-aminolevulinic acid dehydratase from kidney, brain, and liver of adult mice. *Brazilian Journal of Medical and Biological Research*, 32, 761-766.
- Sinska E., Kanoniuk D., Kusiak A. (2004). Aluminium hemotoxicity mechanisms. *Annales Universitatis Mariae Curie Sklodowska Sectio D: Medicina*, 59, 411-416.
- Spencer A.J., Wood J.A., Saunders H.C., Freeman S.L., Lote C.J. (1995). Aluminium deposition in liver and kidney following acute intravenous administration of aluminium chloride or citrate in conscious rats. *Human & Experimental Toxicology*, 14, 787-794.
- Sun X., Cao Z., Zhang Q., Liu S., Xu F., Che J., Zhu Y., Li Y., Pan C., Liang W. (2015). Aluminium trichloride impairs bone and downregulates Wnt/ $\beta$ -catenin signaling pathway in young growing rats. *Food and Chemical Toxicology*, 86, 154-162.
- Wei H., Frenkel K. (1991). In vivo formation of oxidized DNA bases in tumor promoter treated mouse skin. *Cancer Research*, 51, 4443-4449.
- Wendel A. (1981). Glutathione peroxidase. *Methods in Enzymology*, 77, 325-333.
- Wroblewski F. (1957). Clinical significance of serum enzyme alterations with myocardial infarction. *American Heart Journal*, 54, 219-224.
- Yousef M.I. (2004). Aluminium-induced changes in hemato-biochemical parameters, lipid peroxidation and enzyme activities of male rabbits: protective role of ascorbic acid. *Toxicology*, 199, 47-57.
- Yu H., Zhang J., Ji Q., Yu K., Wang P., Song M., Cao Z., Zhang X., Li Y. (2019). Melatonin alleviates aluminium chloride-induced immunotoxicity by inhibiting oxidative stress and apoptosis associated with the activation of Nrf2 signaling pathway. *Ecotoxicology and Environmental Safety*, 173, 131-141.
- Zatta P., Kiss T., Suwalsky M., Berthon M. (2002). Aluminium (III) as a promoter of cellular oxidation. *Coordination Chemistry Reviews*, 228, 271-284.
- Zhu Y., Han Y., Zhao H., Li J., Hu C. Li Y., Zhang Z. (2013). Suppressive effect of accumulated aluminum trichloride on the hepatic microsomal cytochrome P450 enzyme system in rats. *Food Chemical Toxicology*, 51, 210-214.