



EVALUATION OF CHANGES IN NASOPALATINE CANAL MORPHOLOGY ACCORDING TO DENTITION STATUS BY COMPUTED TOMOGRAPHY

NAZOPALATİN KANAL MORFOLOJİSİNİN DENTİSYON DURUMUNA GÖRE DEĞİŞİMİNİN BİLGİSAYARLI TOMOGRAFİ İLE İNCELENMESİ

Ceren Aktuna Belgin^{1*}, Gözde Serindere¹

¹Hatay Mustafa Kemal University, Faculty of Dentistry, Department of Dentomaxillofacial Radiology, Hatay, Turkey

ORCID iD: Ceren Aktuna Belgin: 0000-0001-7780-3395; Gözde Serindere: 0000-0001-7439-3554

***Sorumlu Yazar / Corresponding Author:** Ceren Aktuna Belgin, e-posta / e-mail: dtcaktuna@gmail.com

Geliş Tarihi / Received: 13.01.2020

Kabul Tarihi / Accepted: 16.09.2020

Yayın Tarihi / Published: 02.10.2020

Abstract

Objective: The nasopalatine canal (NPC) is one of the important anatomic structures in anterior maxilla. The aim of this study was to evaluate the changes in NPC morphology according to dentition status in the maxillary anterior region by computed tomography (CT).

Methods: Computed tomography images of 100 patients were screened retrospectively. Images were divided into two groups by dental status: an edentulous group (EG) of 50 patients who have edentulous premaxilla and a control group (CG) of 50 patients who have all incisor teeth in the premaxillary region. After recording the age, sex, and dentition status of the patients, the NPC diameter, NPC length, incisive foramen (IF) diameter, and angle between the NPC and palatine bone were measured in sagittal sections, and the number of NPCs was determined in axial sections.

Results: There was no significant difference between NPC angle and dentition status ($p=0.151$). The NPC diameter was significantly higher in the EG ($p=0.002$), as was the IF diameter ($p=0.041$). In addition, NPC length was significantly higher in the CG ($p<0.001$). A statistically significant and negative correlation was found between age and NPC length ($p<0.001$), and a positive correlation was found between age and NPC diameter ($p=0.004$). In addition, no statistically significant difference was found between sex and other parameters ($p>0.05$).

Conclusion: The NPC length and diameter vary according to the age and dentition status of the patient. Changes in this anatomic structure should be evaluated pre-operatively in elderly patients by three-dimensional radiographic evaluation.

Keywords: *Computed tomography, nasopalatine canal, anatomy, dentition, incisive foramen*

Öz

Amaç: Nazopalatin kanal maksiller anterior bölgedeki önemli anatomik oluşumlardan biridir. Bu çalışmanın amacı nazopalatin (NP) kanal morfolojisinin dentisyon durumuna göre değişimini bilgisayarlı tomografi (BT) ile incelemektir.

Yöntem: Toplam 100 hastaya ait bilgisayarlı tomografi görüntüleri retrospektif olarak taranmıştır. Bilgisayarlı tomografi görüntüleri iki gruba ayrıldı: maksiller ön bölgesi dişsiz olan (DG) 50 hasta ve maksiller ön bölgede diş kaybı olmayan, kontrol grubu (KG) olarak adlandırılan 50 hasta. Hastaların yaş, cinsiyet ve dentisyon durumları not edildikten sonra sagittal kesit üzerinde NP kanal uzunluğu, insiziv foramen çapı, NP kanal çapı ve NP kanal ile sert damak arasındaki nazopalatin kanal açısı ölçülmüştür. Aksiyal kesitler üzerinde ise NP kanal sayısı tespit edilmiştir.

Bulgular: Nazopalatin açısı ile dentisyon durumu arasında istatistiksel olarak anlamlı bir fark bulunmamıştır ($p=0,151$). IF çapı DG da istatistiksel olarak anlamlı derecede daha yüksek bulunmuştur ($p=0,041$). Nazopalatin kanal uzunluğu ise KG da anlamlı derecede yüksek bulunmuştur ($p<0,001$). Yaş ve NP uzunluğu arasında anlamlı derecede negatif ($p<0,001$), yaş ve NP kanal çapı arasında ise anlamlı derecede pozitif korelasyon tespit edilmiştir ($p=0,004$). Buna karşılık cinsiyet ve parametreler arasında anlamlı bir fark bulunmamıştır ($p>0,05$).

Sonuç: Nazopalatin kanal uzunluğu ve çapı hastaların yaşı ve dentisyon durumuna göre değişmektedir. İleri yaştaki hastalarda üç boyutlu radyografilerle bu anatomik yapıların değişimi preoperative olarak değerlendirilmelidir.

Anahtar Kelimeler: *Bilgisayarlı tomografi, nazopalatin kanal, anatomi, dentisyon, insiziv foramen*

Introduction

The nasopalatine canal (NPC) is the anatomical structure located in the premaxilla region that connects the hard palate to the nasal floor. The NPC opens to the oral cavity with called incisive foramen which is behind the maxillary central teeth.¹ Considering the presence of neurovascular structures within the NPC, for surgical procedures, dental implant surgery, or anesthesia, evaluation of morphology and size before surgery is crucial to prevent possible complications. Contact of dental implants with neural structures may affect the implant osseointegration or may cause neural dysfunction.^{2,3} In addition, difficulties related to NPC anatomy while performing local anesthesia in the maxillary anterior region have been reported in the literature.⁴

The importance of preoperative evaluation of the NPC region has increased, with the increasing rehabilitation of toothless maxilla through dental implants. In the literature, there is a correlation between the loss of maxillary incisors and changes in NPC morphology.⁵ Bone atrophy that develops after tooth loss may affect the surrounding structures, and the NPC may enlarge and the neurovascular structures within it may become close to the alveolar crest.⁴ The NPC was evaluated by micro-computed tomography⁶ or magnetic resonance imaging⁷, but to prevent perforation of the base of the nose and to prevent damage to neurovascular structures in the NPC, the use of computed tomography (CT) before surgical operations has been recommended in the literature.⁸ It is stated that CT is preferred because it can transfer information in three dimensions, and distortions and superpositions are less common than in conventional radiography.^{8,9} Although there are articles in the literature using cone-beam CT for NPC morphology^{10,11}, and cone beam CT has a relatively lower radiation dose comparing with medical CT, CT images were preferred in this study because the contrast resolution of CT was higher than that of cone-beam CT.¹²

Anatomical variations in the NPC; the form, length, location, and incisive foramen (IF) diameter; the number of openings in the nasal fossa; and other morphological changes have been evaluated in the literature.^{11,13} However, there are few articles evaluating the relationship between dentition and NPC morphology in the literature.⁴ Therefore, the aim of this study was to evaluate the changes in NPC morphology according to dentition status in the maxillary anterior region by CT. The null hypothesis stated that there were no differences between NPC morphology and dentition status.

Methods

The Local Ethics Committee of Hatay Mustafa Kemal University (Decision no: 20, Date: 31/10/2019) approved this retrospective study, and the study protocol was conducted following the principles of the Declaration of Helsinki.

In this study, CT images of patients who applied to the Department of Dentomaxillofacial Radiology of our faculty for various reasons, such as temporomandibular joint disorders, maxillary sinus pathology, etc., between 2017-2019 were investigated. Poor quality images or artificial problems related to CT, patients who had undergone any operation or trauma to the maxillary anterior region, patients with any pathology affecting the maxilla anterior region, and

patients with cleft palate in this region were excluded from the study.

In total, 100 CT images taken with a 64-row MDCT scanner (Toshiba Aquilion, Toshiba Medical Systems, Otawara, Japan) in accordance with the standard maxillofacial radiography format for each patient were analyzed retrospectively. Computed tomography images were divided into two groups by dental status: an EG of 50 patients (21 females, 29 males) who have edentulous premaxilla and a CG of 50 patients (23 females, 27 males) who have all incisor teeth in the premaxillary region.

After recording the age, sex, and dentition status of the patients, based on the study of Bahsi et al.¹⁴, the NPC diameter, NPC length, IF diameter, and angle between the NPC and palatine bone were measured in sagittal sections (Figure 1), and the number of NPCs was determined in axial sections (Figure 2). All measurements were performed using Image J (1.4 v, National Institutes of Health, Bethesda, MD). Image evaluation and measurements were performed by two dentomaxillofacial radiologists, one with six years and one with five years of clinical experience, and calibrated for reference point selection. To assess inter-observer compliance, 20% of all measurements were repeated after two weeks.

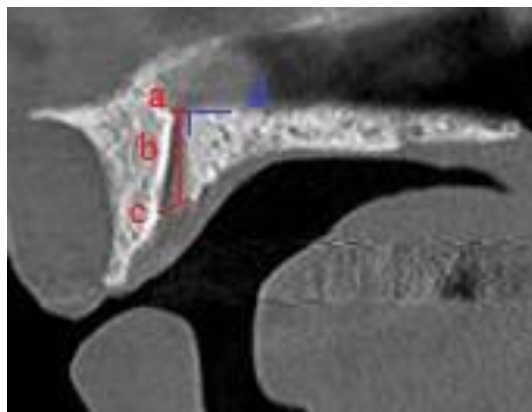


Figure 1. Measurement of NPC diameter, NPC length, IF diameter and angle of NPC in sagittal sections. a: NPC diameter, b: NPC length, c: IF diameter, d: angle of NPC

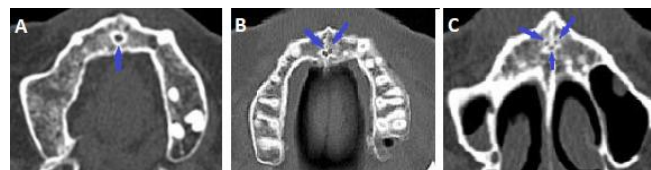

Figure 2. The number of NP canal in axial section. A: One NP canal, B: Two NP canal, C: Three NP canal.

Statistical analysis

Statistical analyses were evaluated using the SPSS 21.0 software (SPSS Inc., Chicago, IL, USA). The conformity of the parameters to a normal distribution was performed using the Kolmogorov–Smirnov test. Comparisons were made with the Student's t-test for normal distribution variables and the Mann–Whitney U test for non-normally distributed variables. The relationship between variables was analyzed by correlation analysis. *P* values <0.05 were considered to indicate statistical significance. Intraclass correlations (ICC) were calculated for inter-observer compliance.

Results

The inter-observer ICC value was 0.891 (95% CI: 0.743–0.942). The mean age in the EG and CG were 67±10.54 years (range 32–84 years) and 38±15.66 years (range 16–67 years), respectively. There was no significant difference between angle of NPC and two dentition status ($p=0.151$). The NPC diameter was significantly higher in the EG (2.19 mm) than the CG (1.62 mm) ($p=0.002$), and the IF diameter was significantly higher in the EG (2.69 mm) than the CG (2.31 mm) ($p=0.041$). The distribution of EG and CG according to angle of NPC, NPC diameter, and IF diameter is shown in Table 1. In the CG, one NPC was found in 41 CTs (82%), two NPCs were noted in six cases (12%), and three NPCs were noted in another three cases (17%). In the EG, one NPC was found in 35 CTs (70%), two in 10 CTs (20%), and three in five CTs (10%). There was no

statistically significant difference in the number of NPCs between the groups. The NPC length was significantly longer in the CG (11.04 mm) than the EG (8.02 mm) ($p=0.0001$). A comparison between two dentition status and NPC length is shown in Table 2. There was a statistically significant and negative correlation between age and NPC length ($p<0.001$). On the other hand, there was a statistically significant and positive correlation between age and NPC diameter ($p=0.004$). It was found that NPC length decreased with increasing age, whereas NPC diameter increased. There was no statistically significant correlation between angle of NPC ($p=0.966$), IF diameter ($p=0.068$), and NPC number ($p=0.882$) and age. In addition, no statistically significant difference was found between sex and other parameters ($p>0.05$). A comparison between the other parameters and sex is shown in Table 3.

Table 1. Distribution of EG and CG according to angle of NPC, NPC diameter and IF diameter

		n	Mean	Median	Minimum	Maximum	SD	Mann-Whitney U test	
								Mean Rank	p
NP Angle (°)	CG	50	120.94°	122.05°	11.05°	155.90°	22.99°	54.7	0.151
	EG	50	117.13°	116.70°	85.60°	147.10°	16.75°	46.3	
	Total	100	119.04°	118.25°	11.05°	155.90°	20.10°		
NP Canal Diameter (mm)	CG	50	1.62	1.30	0.43	4.26	0.84	41.7	0.002*
	EG	50	2.19	2.01	0.43	4.34	0.96	59.4	
	Total	100	1.90	1.69	0.43	4.34	0.94		
IF Diameter (mm)	CG	50	2.31	1.95	0.43	5.61	1.22	44.6	0.041*
	EG	50	2.69	2.78	0.60	4.64	0.96	56.5	
	Total	100	2.50	2.34	0.43	5.61	1.11		

*Statistically significant is bold. SD: Standard deviation, CG: Control group, EG: Edentulous group, NP: Nasopalatin, IF: Incisive foramen, mm: Millimeter

Table 2. Comparison between two dentition status and NPC length

		n	Mean	Median	Minimum	Maximum	SD	Student's t test	
								t	p
NP Canal Length (mm)	CG	50	11.04	10.89	5.60	17.59	2.58	6.7	0.0001*
	EG	50	8.02	8.13	2.33	11.06	1.84		
	Total	100	9.53	9.40	2.33	17.59	2.70		

*Statistically significant is bold. SD: Standard deviation, CG: Control group, EG: Edentulous group, NP: Nasopalatin, IF: Incisive foramen, mm: Millimeter

Table 3. Comparison between the other parameters and sex

		n	Mean	Median	Minimum	Maximum	SD	Mann-Whitney U Test	
								Mean Rank	p
NP Angle (°)	Male	56	117.71°	117.05°	85.60°	151.70°	17.15°	46.7	0.141
	Female	44	120.72°	119.90°	11.05°	155.90°	23.43°	55.3	
	Total	100	119.04°	118.25°	11.05°	155.90°	20.10°		
NP Canal Length (mm)	Male	56	9.88	9.78	2.33	17.59	3.15	53.7	0.208
	Female	44	9.08	9.09	5.19	13.06	1.92	46.4	
	Total	100	9.53	9.40	2.33	17.59	2.70		
NP Canal Diameter (mm)	Male	56	2.06	1.85	0.43	4.34	1.07	54.1	0.161
	Female	44	1.71	1.40	0.60	3.47	0.73	45.9	
	Total	100	1.90	1.69	0.43	4.34	0.94		
IF diameter (mm)	Male	56	2.55	2.42	0.43	5.61	1.23	51.5	0.691
	Female	44	2.43	2.27	1.04	4.60	0.94	49.2	
	Total	100	2.50	2.34	0.43	5.61	1.11		
NP Canal Number (mm)	Male	56	1.25	1.00	1.00	3.00	0.55	51.2	0.678
	Female	44	1.23	1.00	1.00	3.00	0.57	49.6	
	Total	100	1.24	1.00	1.00	3.00	0.55		

SD: Standard deviation, NP: Nasopalatin, IF: Incisive foramen, mm: Millimeter

Discussion

The NPC is an anatomic landmark located at the palatine of the central maxillary incisors, connecting the nasal cavity to the palate and containing the NP (incisive) nerve, the terminal branch of the NP artery and fibrous connective tissue, fat and small salivary glands.^{15,16} In the literature, it was stated that implant placement in this region is not possible in 4% of cases due to NPC size.⁵ In such cases, techniques recommending implantation of the maxillary anterior by adjusting the bone graft to fit the foramen when retracting the soft tissue content have been proposed in the literature.² Another issue is, atrophic edentulous anterior maxilla rehabilitation using dental implant surgery, which becomes difficult as a result of shortening of NPC length after anterior region tooth extraction.¹⁷

Liang et al.¹⁸ in their study evaluated the anatomic variability and characteristics of the NPC using an anatomical, histological, and CT scan, and they stated that one NPC was detected in 53 cases (44%), two in 47 cases (39%), and three or four in 20 cases (17%). As another result, they reported that the mean NPC diameter was 3.5 mm and 3.6 mm, and the mean NPC length was 10.6 mm and 9.2 mm, respectively, in the dentate and edentulous groups. According to these findings, they identified a significant difference between age and NPC diameter but no significant difference between the NPC diameter and dentition. In addition, they found that the NPC was significantly longer in the dentate group and that males have significantly longer and wider canals. In present study, although there was no significant difference between genders in terms of NPC length, numerical results close to those of Liang et al. were obtained.¹⁸

Bahsi et al.¹⁴ reported a negative correlation between age and NPC angle. They thought that the angle of NPC decreased due to resorption of the palate as age progresses and a statistically significant difference was found between IF diameter and sex. Contrary to Bahsi et al.¹⁴, no significant difference was found between age and gender in terms of angle of NPC and IF diameter in our study.

Mardinger et al.⁴ stated that the diameter of the NPC widened with age, which could be confirmed in the present study. They reported that this was similar to hyperpneumatizing the maxillary sinus after tooth extraction in the maxillary posterior. They stated that the enlargements were mainly due to bone loss after tooth extraction.

In another study,¹⁰ examined the NPC morphometric and volumetric measurement in anterior edentulous and anterior dentate in cone beam CT images. They found that there was no relationship between two dentition status and NPC volume. Similar to present study, they stated that the NPC length decreased by bone resorption.

The IF diameter is thought to be less than 6 mm in general, and it is accepted that it may be pathologic if it exceeds 10 mm.^{19,20} In present study, the mean IF diameter was 2.5 mm (range 0.43–5.61 mm). Particular attention should be paid to the IF diameter during surgical procedures and implant operations in the maxilla anterior region.

In current study, it was observed that the NPC angle did not differ with dentition status, but the NPC and IF diameters increased with tooth loss in the maxillary anterior region. The length of the NPC was shortened due to age and tooth loss in the maxillary anterior region. It was thought that there was a correlation between these parameters because of more frequent tooth loss in older patients. It was seen that gender did not affect NPC length, angle of NPC, NPC and

IF diameters, NPC number. As a limitation of this study, it can be extended to reach morphological data in the population and to investigate average data in the general population by increasing the sample size. In addition, measurements of each IF diameter in patients with more than one IF can be included in the study. Another limitation is the selection of the same reference points in the measurements made by different observers. In order to solve this problem, both observers were calibrated for reference points before the study and measurements were repeated to test the reliability of the measurements. Also, in the measurements performed on standard maxillofacial radiographs taken from the same technique from each patient, measurements were made on the same screen and the same software to ensure standardization.

In conclusion, especially in older patients, changes in NPC length and NPC diameter may occur with increasing tooth loss in the maxillary anterior region. These changes can be easily observed on three-dimensional radiographs. Therefore, it is recommended to evaluate the length and diameter of the NP canal, which changes with age, in three-dimensional before surgical interventions such as dental implant, cyst operation etc. in the maxillary anterior region.

Conflicts of Interest

The authors declare no conflicts of interest.

Compliance of Ethical Statement

This study was approved by the Local Ethics Committee of Hatay Mustafa Kemal University (Decision no: 20, Date: 31/10/2019).

Financial Disclosure/Funding

The authors declare no financial support.

Author Contribution

CAB: Study conception and design; CAB, GS: Data Collection, literature search, resources, statistical analysis; CAB: Manuscript drafting/writing; GS: Manuscript Editing

References

1. Thakur AR, Burde K, Guttal K, Naikmasur VG. Anatomy and morphology of the nasopalatine canal using cone-beam computed tomography. *Imaging Sci Dent.* 2013;43(4):273-281. doi:10.5624/isd.2013.43.4.273
2. Artzi Z, Nemcovsky CE, Bitlilitum I, Segal P. Displacement of the incisive foramen in conjunction with implant placement in the anterior maxilla without jeopardizing vitality of nasopalatine nerve and vessels: a novel surgical approach. *Clin Oral Implants Res.* 2000;11(5):505-510. doi:10.1034/j.1600-0501.2000.011005505.x
3. Casado PL, Donner M, Pascarelli B, Derocy C, Duarte ME, Barboza EP. Immediate dental implant failure associated with nasopalatine duct cyst. *Implant Dent.* 2008;17(2):169-175. doi:10.1097/ID.0b013e3181776c52.4
4. Mardinger O, Namani-Sadan N, Chaushu G, Schwartz-Arad D. Morphologic changes of the nasopalatine canal related to dental implantation: a radiologic study in different degrees of absorbed maxillae. *J Periodontol.* 2008;79(9):1659-1662. doi:10.1902/jop.2008.080043
5. Kraut RA, Boyden DK. Location of incisive canal in relation to central incisor implants. *Implant Dent.* 1998;7(3):221-225. doi:10.1097/00008505-199807030-00010
6. Song WC, Jo DI, Lee JY, et al. Microanatomy of the incisive canal using three-dimensional reconstruction of micro CT images: An ex vivo study. *Oral Surg Oral Med Oral Pathol*

- Oral Radiol Endod.* 2009;108(4):583-590. doi:10.1016/j.tripleo.2009.06.036
7. Jacobs R, Lambrechts I, Liang X, et al. Neurovascularization of the anterior jaw bones revisited using high-resolution magnetic resonance imaging. *Oral Surg Oral Med Oral Pathol Oral Radiol Endod.* 2007;103(5):683-693. doi:10.1016/j.tripleo.2006.11.0148
 8. Cavalcanti MG, Yang J, Ruprecht A, Vannier MW. Accurate linear measurements in the anterior maxilla using orthoradially reformatted spiral computed tomography. *Dentomaxillofac Radiol.* 1999;28(3):137-140. doi:10.1038/sj/dmfr/4600426
 9. Besimo C, Lambrecht J, Nidecker A. Dental implant treatment planning with reformatted computed tomography. *Dentomaxillofac Radiol.* 1995;24(4):264-267. doi:10.1259/dmfr.24.4.9161173
 10. Demiralp KÖ, Kurşun-Çakmak EŞ, Bayrak S, Sahin O, Atakan C, Orhan K. Evaluation of anatomical and volumetric characteristics of the nasopalatine canal in anterior dentate and edentulous individuals: A CBCT Study. *Implant Dent.* 2018;27(4):474-479. doi:10.1097/ID.0000000000000794.
 11. Al-Amery SM, Nambiar P, Jamaludin M, John J, Ngeow WC. Cone beam computed tomography assessment of the maxillary incisive canal and foramen: considerations of anatomical variations when placing immediate implants. *PLoSOne.* 2015;10(2):e0117251. doi:10.1371/journal.pone.0117251
 12. Angelopoulos C, Scarfe WC, Farman AG. A comparison of maxillofacial CBCT and medical CT. *Atlas Oral Maxillofac Surg Clin North Am.* 2012;20(1):1-17. doi:10.1016/j.cxom.2011.12.008.
 13. Kraut R. Interactive CT diagnosis, planning and preparation for dental implants. *Implant Dent.* 1998;7(1):19-25. doi:10.1097/00008505-199804000-00002
 14. Bahşi I, Orhan M, Kervancıoğlu P, Yalçın ED, Aktan AM. Anatomical evaluation of nasopalatine canal on cone beam computed tomography images. *Folia Morphol (Warsz).* 2019;78(1):153-162. doi:10.5603/FM.a2018.0062
 15. Bornstein MM, Balsiger R, Sendi P, von Arx T. Morphology of the nasopalatine canal and dental implant surgery: a radiographic analysis of 100 consecutive patients using limited cone-beam computed tomography. *Clin Oral Impl Res.* 2011;22(3):295-301. doi:10.1111/j.1600-0501.2010.02010.x
 16. Neves FS, Oliveira LK, Ramos Mariz AC, Crusóé-Rebello I, de Oliveira-Santos C. Rare anatomical variation related to the nasopalatine canal. *Surg Radiol Anat.* 2013;35(9):853-855. doi:10.1007/s00276-013-1089-1
 17. Moya-Villaescusa MJ, Sánchez- Pérez A. Measurement of ridge alterations following tooth removal: A radiographic study in humans. *Clin Oral Implants Res.* 2010;21(2):237-242. doi:10.1111/j.1600-0501.2009.01831.x
 18. Liang X, Jacobs R, Martens W, et al. Macro- and micro-anatomical, histological and computed tomography scan characterization of the nasopalatine canal. *J Clin Periodontol.* 2009;36(7):598-603. doi:10.1111/j.1600-051X.2009.01429.x.
 19. Swanson KS, Kaugars GE, Gunsolley JC. Nasopalatine duct cyst: an analysis of 334 cases. *J Oral Maxillofac Surg.* 1991;49(3):268-271. doi:10.1016/0278-2391(91)90217-a
 20. Kreidler JF, Raubenheimer EJ, Van Heerden WF. A retrospective analysis of 67 cystic lesions of the jaw—the Ulm experience. *J Craniomaxillofac Surg.* 1993;21(8):339-341. doi:10.1016/s1010-5182(05)80494-9