

# Removal of an Adhered Implant Cover Screw: A Case Report

## Sıkışmış Bir İyileşme Başlığının Çıkartılması: Olgu Sunumu

### ABSTRACT

Dental implants have become one of the most popular technique for replacing missing teeth and implant therapy is an effective and reliable prosthodontic treatment option. Complications like mechanical or biological can be directly effected the success of the treatment modality. The screw mechanical complications like screw loosening or fracture are the most reported complications in the literature. The adhered cover screw is a rare complication. The purpose of this case report is to present a solution for a mechanical failure.

**Key words:** Dental implant, Complication, Adhered screw

### ÖZ

Dental implantlar, kayıp dişlerin yerine konulmasında en popüler tekniklerden biri olmuştur ve implant tedavisi efektif ve başarılı bir prostodontik tedavi seçeneğidir. Mekanik ve biyolojik komplikasyonlar bu tedavi seçeneğinin başarısını direkt olarak etkileyebilmektedir. Vida kırıkları ve gevşemeleri gibi mekanik komplikasyonlar literatürde en çok raporlanan komplikasyonlardır. Kapama vidasının soğuk füzyonu ve metal kaynaşması çok nadir bir komplikasyondur. Bu olgu sunumunun amacı bu tür bir mekanik komplikasyona çözüm yönteminin sunulmasıdır.

**Anahtar sözcükler:** Dental implant, Komplikasyon, Sıkışmış implant vidası

### INTRODUCTION

Dental implants have become one of the most popular technique for replacing missing teeth and implant therapy is an effective and reliable prosthodontic treatment option (1, 2). The longevity of an implant retained or supported prosthesis is dependent upon both biological and mechanical factors. Biological complications associated with dental implants can lead to implant failure and to its loss. Implant failure can be divided into two categories. The first, early failures, occurs no later than 6 months after implantation or before the implants are loaded (3, 4). Early failures are mainly of a biological nature. First are the biological causes, such as progressive loss of bone support as a result of infection or inflammation known as peri-implantitis (5).

The second cause for implant loss is related to mechanical complications. Mechanically, the implant, its component parts (the transmucosal abutment and abutment screw), or the prosthesis (including prosthetic screws where applicable) may fail. Mechanical complications include screw drive deformation, screw loosening, screw fracture, prosthesis fracture and problems with attachments (6, 7). According to a previous study, more than half

İbrahim DURAN<sup>1</sup>

Betül YILMAZ<sup>1</sup>

Mahmut SÜMER<sup>2</sup>

Berre KARÖZ<sup>2</sup>

Çağrı URAL<sup>1</sup>

<sup>1</sup> Ondokuz Mayıs University, Faculty of Dentistry, Department of Prosthodontics, Samsun, Turkey

<sup>2</sup> Ondokuz Mayıs University, Faculty of Dentistry, Department of Oral and Maxillofacial, Samsun, Turkey



Received / *Geliş tarihi* : 01.11.2015

Accepted / *Kabul tarihi*: 02.12.2015

DOI: 10.21306/jids.2015.1.14

### Corresponding Adress/İletişim Adresi:

Çağrı URAL

Ondokuz Mayıs University,

Faculty of Dentistry,

Department of Prosthodontics,

Samsun, Turkey

Phone/Tel: 0 362 312 1919 / 3690

E-mail/E-posta: cagriural@omu.edu.tr

(58%) of the implants experienced at least one mechanical complication (6). Many retrospective clinical studies have reported a high incidence of screw loosening and/or fracture (8). In related literature the screw problems in implants were reported as %17 of all mechanical problems (4). There are a lot of studies which were reported the screw complications like abutment screw loosening (9, 10), abutment screw fracture (11)#, prosthesis screw fracture (12). However, adhered cover screw to implant body is a rare complication in the literature.

The purpose of this case report is to present a solution for a mechanical failure. The removal of an adhered screw by the help of rotary instruments may cause defects on implant neck during the performing removing procedure. These defects may cause misfit at marginal region and also this may cause some biological defects like peri-implantitis. As a result, the method for removing healing cap that presented in this case report may be a safe solution for the clinicians.

### CASE REPORT

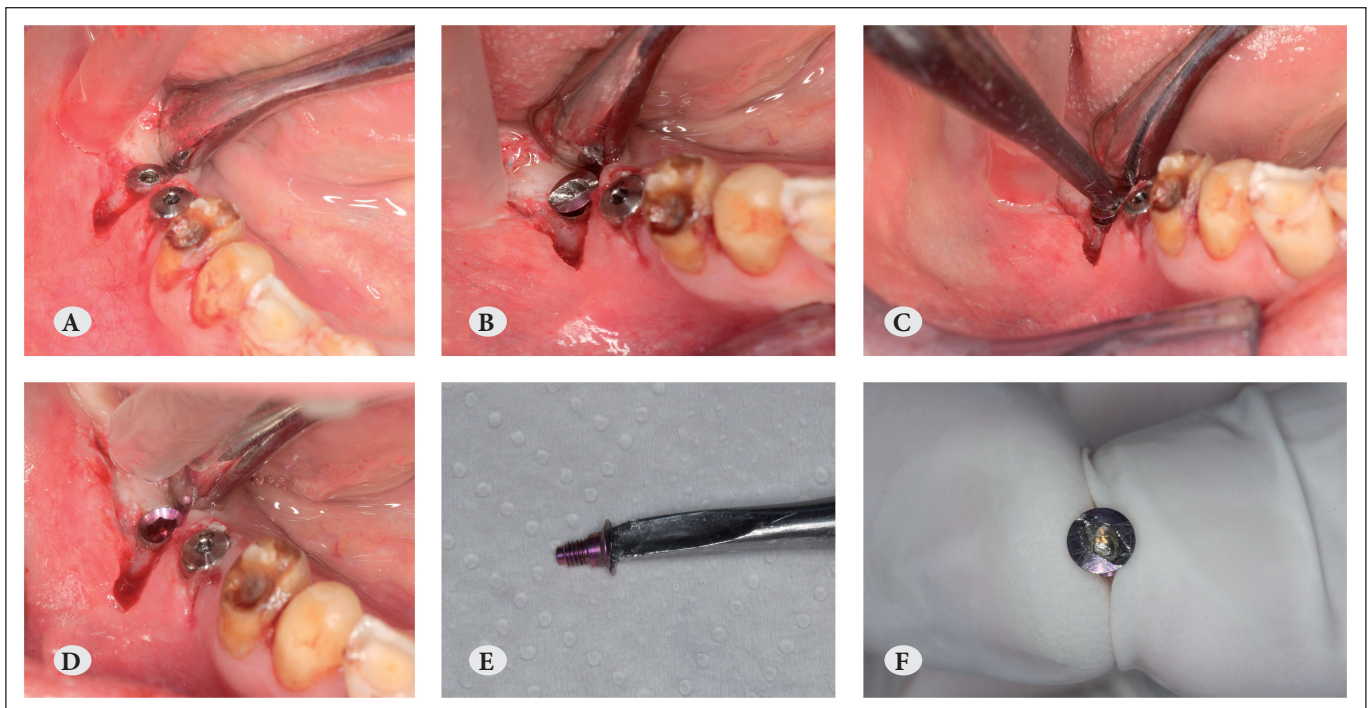
A 57-year-old partially edentulous male was presented to Ondokuz Mayıs University Department of Prosthodontics with functional and esthetic problem. Clinically and radiographic examination were done and planned implant in posterior region.

Surgical procedure was planned and extended healing period of three months. Second stage surgery was performed but complication was encountered while unscrewing the cover screw of implant with a hex driver. The drive of the cover screw was deformed, probably because of excessive load while unscrewing. We couldn't overcome the complication by using a new hex driver so decided to create a slot on cover screw. The slot was made by grooving the cover screw with a diamond tapering fissure bur using different technique. Groove was prepared in the form of semilunar for prevent damage to the inner surface of the implant. The cover screw was retrieved easily using the modified elevator (Figure 1).

### DISCUSSION

The presented case illustrates a complication that occurs with the inherent part of implant components. The method of perforating the healing cap first and achieving retention to unscrew it afterwards was successful. However, the method is difficult and time-consuming and involves the risk of damaging the neck of the implant.

Mechanical complications include screw loosening, screw fractures, implant fractures, framework/resin/veneering material fractures, implant prosthesis fractures, opposing prosthesis fractures, and overdenture mechanical retention problems (13). Abutment screw



**Figure 1:** A) Implant and adhered cover screw in the mandible, B) The semilunar slot that made on the cover screw, C) Using of an elevator for turning the screw, D) Removed cover screw, E) The cover screw removed with elevator, F) The slot on cover screw.

loosening was reported in a large number of studies and ranged from 2% to 45% of the abutments. Prosthesis screw loosening ranged from 1% to 38% in the 13 studies reporting this complication (13). There is only one literature was found that reports a complication of adherence cover screw, Bhuvanesarri and Chandrasekaran (2) explained to remove of an adhered cover screw in an implant. They made a straight slot on the cover screw to engage the straight screw driver but flat screw holes can be a bit problematic because of the risk of damaging the inner surface of the implant. In the present case the slot was prepared semilunar for prevent the damaging. The technique described in this article involves the use of inexpensive instruments commonly found in dental offices and by using this modified technique, it is easy to prevent the damage of internal surface of the implants. Nevertheless, the aim of treatment should be to avoid entrenched of implant cover screw and to use the described repair procedure only in necessary circumstances. This technique can be used in exceptional clinical situation. Avoiding such clinical situation is first treatment modality.

### Conclusion

In the limitations of this study the following statements can be drawn ;

1. Adherence of cover screw is a rare mechanical complication,
2. Making a semilunar slot on the cover screw is a safety method for removing the screw without any damage to implant body.

### REFERENCES

1. Kern M, Wegner SM. Bonding to zirconia ceramic: adhesion methods and their durability. *Dent Mater* 1998;14:64-71.
2. Bhuvanesarri J, Chandrasekaran SC. A technique elucidating the retrieval of an adhered cover screw in a dental implant - a case report. *J Clin Diagn Res* 2013;7:2642-2643.
3. Tonetti MS, Schmid J. Pathogenesis of implant failures. *Periodontol* 2000 1994;4:127-138.
4. Goodacre CJ, Bernal G, Rungcharassaeng K, Kan JY. Clinical complications with implants and implant prostheses. *J Prosthet Dent* 2003;90:121-132.
5. Shemtov-Yona K, Rittel D. An Overview of the Mechanical Integrity of Dental Implants. *Biomed Res Int* 2015;2015:547384.
6. Simonis P, Dufour T, Tenenbaum H. Long-term implant survival and success: a 10-16-year follow-up of non-submerged dental implants. *Clin Oral Implants Res* 2010;21:772-777.
7. Papaspyridakos P, Chen CJ, Chuang SK, Weber HP, Gallucci GO. A systematic review of biologic and technical complications with fixed implant rehabilitations for edentulous patients. *Int J Oral Maxillofac Implants* 2012;27:102-110.
8. Schwarz MS. Mechanical complications of dental implants. *Clin Oral Implants Res* 2000;11:156-158.
9. Jemt T, Laney WR, Harris D, Henry PJ, Krogh PH, Jr., Polizzi G, et al. Osseointegrated implants for single tooth replacement: a 1-year report from a multicenter prospective study. *Int J Oral Maxillofac Implants* 1991;6:29-36.
10. Jemt T. Failures and complications in 391 consecutively inserted fixed prostheses supported by Branemark implants in edentulous jaws: a study of treatment from the time of prosthesis placement to the first annual checkup. *Int J Oral Maxillofac Implants* 1991;6:270-276.
11. Allen PF, McMillan AS, Smith DG. Complications and maintenance requirements of implant-supported prostheses provided in a UK dental hospital. *Br Dent J* 1997;182:298-302.
12. Naert I, Quirynen M, Theuniers G, van Steenberghe D. Prosthetic aspects of osseointegrated fixtures supporting overdentures. A 4-year report. *J Prosthet Dent* 1991;65:671-680.
13. Goodacre CJ, Kan JY, Rungcharassaeng K. Clinical complications of osseointegrated implants. *J Prosthet Dent* 1999;81:537-552.