



Case Report

J. Exp. Clin. Med., 2019; 36(3): 95-97  
doi: 10.5835/jecm.omu.36.03.006



## Wunderlich Syndrome: A case report

Ramazan Sami Aktaş\*, Sevdegiil Karadaş, Veysel Eskin, Gizem Gizli

Department of Emergency Medicine, Faculty of Medicine, Yüzüncü Yıl University, Van, Turkey

### ARTICLE INFO

#### Article History

Received 16 / 10 / 2019  
Accepted 27 / 12 / 2019  
Online Published 10 / 02 / 2020

#### \* Correspondence to:

Ramazan Sami Aktaş  
Department of Emergency Medicine,  
Faculty of Medicine,  
Yüzüncü Yıl University, Van, Turkey  
e-mail: ramazansamiaktas@gmail.com

#### Keywords:

Emergency medicine  
Nephrectomy  
Spontaneous retroperitoneal bleeding  
Wunderlich syndrome

### ABSTRACT

Wunderlich syndrome is a rare cause of abdominal pain. This is spontaneous, nontraumatic kidney bleeding confined to the subcapsular and perirenal space. Various terms have been used including spontaneous perirenal haematoma, spontaneous subcapsular renal haemorrhage, nontraumatic perirenal haematoma and spontaneous perinephric haematoma. The etiology of spontaneous renal rupture has not been described yet. Possible causes include benign [e.g., angiomyolipomas (AML), tuberous sclerosis, renal cyst, adenoma, lipoma, and hamartoma] and malignant (e.g., oncocytoma, renal clear cell carcinoma, and Wilms' tumor) tumors or it can occur secondary to vasculitis (polyarteritis nodosa), nephritis, blood dyscrasias (anticoagulant agents, polycythaemia), renal stone disease, arteriovenous malformations and fistulas, venous thrombosis or rupture of renal artery/intraparenchymal aneurysm. Clinically this condition presents with acute flank pain, palpable flank mass and hypovolemic shock together known as 'Lenk's triad'. Historically, renal neoplasms followed by vascular diseases were the most common causes of Wunderlich syndrome. Our case was 50 years old woman. A spontaneous retroperitoneal hemorrhage patients who at night come to emergency with sudden abdominal pain. Wunderlich syndrome is cause of unexplained abdominal pain should be kept in mind.

© 2019 OMU

### 1. Introduction

Spontaneous retroperitoneal bleeding (SRC) is a life-threatening clinical condition (Murphy et al., 2013). Wunderlich syndrome (WS) is a rare, spontaneous and non-traumatic retroperitoneal hemorrhage, firstly described by Wunderlich in 1856 (Virchow, 1856). The incidence is not known clearly (Vaddi et al., 2011; Murphy et al., 2013). The classic Lenk's triad is seen in WS. These findings are pain in the unilateral acute phalanx, palpable mass in examination with abdominal palpation and hypovolemic shock indicators. However, the findings are usually nonspecific and variable in the patients (Baishya et al., 2011; Katabathina et al., 2011). There are renal (tumor, vascular and inflammatory diseases) and extrarenal (adrenal diseases, abdominal aortic aneurysm) diseases in the etiology of WS. The

most common causes of WS are renal cell carcinoma and angiomyolipoma (Daskalopoulos et al., 2003). It should also be kept in mind that WS can be seen without the use of anticoagulants and trauma. The diagnosis is made by radiological imaging with clinical suspicion (Kendall et al., 1988; Zhang et al., 2002). The aim of presenting this case is to emphasize the importance of advanced imaging in unexplained abdominal pain to detect rare cases for life-threatening clinical conditions. As a result, it is to increase the awareness of emergency physicians for rare fatal conditions.

### 2. Case

A 50-year-old female patient was admitted to the emergency service with a sudden onset pain in her right upper and lower quadrants. Nausea and vomiting were

accompanied by persistent pain. The patient's medical history included hypertension (HT) and right renal angiomyolipoma. It was learned that the patient was not taking regular medication for HT and was followed up for angiomyolipoma. At the time of presentation, the blood pressure was 135/85 mmHg, pulse rate was 95/min, and the other vital signs were normal. The electrocardiogram (ECG) was showed normal sinus rhythm. Physical examination revealed right upper and lower quadrant tenderness, defense and rebound in the abdomen. The other examination findings were normal. Oral intake of the patient was stopped and the patient was monitorized. 2 L/min oxygen was started with nasal cannula. Vascular access was opened and normal saline infusion was started at a rate of 100 ml/h. In the laboratory tests; Hemoglobin (Hgb) was 11.98 g/dL hematocrit (Htc) was 37.5%, platelet (Plt) was 219300 / uL, INR was 1.08 and the other blood parameters were normal. Control Hgb was measured as 11.3 g/dL. The abdominal x-ray was seemed as normal (Fig. 1). In abdominal ultrasonography (USG); There was no free fluid in the abdomen, the right kidney dimensions could not be evaluated clearly. In the USG which was taken one month ago; a hyperechogenic lesion with vascular structure was seen in the right kidney. The lesion was in size 44 × 23 mm and was properly limited. She underwent computerized abdominal tomography (ACT) with intravenous contrast injection. In the right kidney, approximately 12 × 6 cm hematoma area extending to the superior and inferior of the kidney was seen in the ACT and there was a free fluid of 14 mm in the pelvic region (Fig. 2). The patient was consulted to the urology department because of the increased renal size due to bleeding. The patient underwent emergency

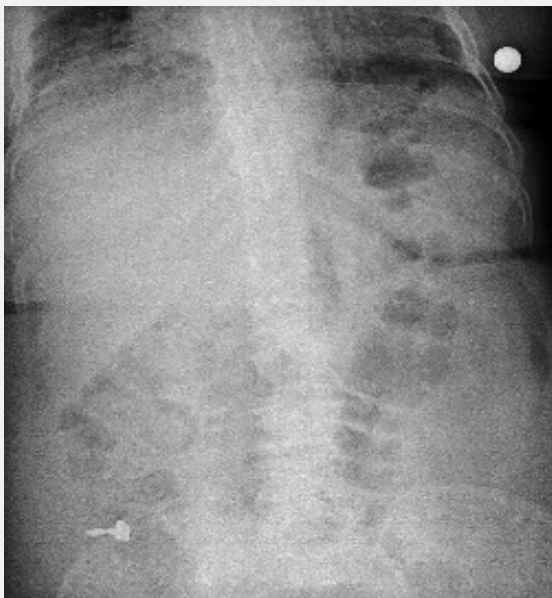


Fig. 1. Direct graphy.

surgery and right nephrectomy was performed. When her general condition improved, she was discharged with a plan of periodic follow-up.

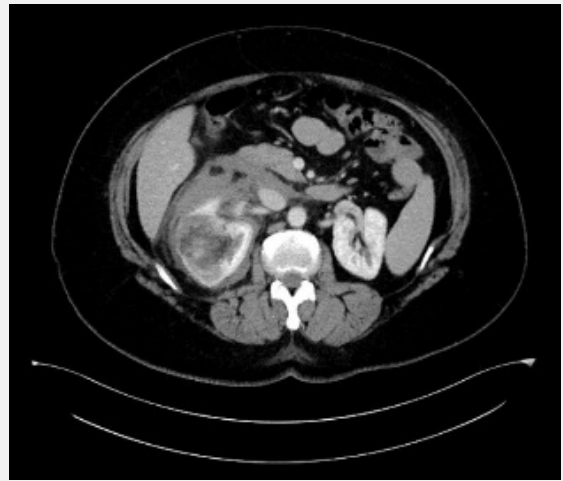

Fig. 2. Computed tomography abdomen scan with contrast.

### 3. Discussion

Spontaneous retroperitoneal hemorrhage is a rare and fatal situation which is presenting to the ED with abdominal pain. (Murphy et al., 2013). Failure to diagnose can result in death. In general, the cases of WS are middle-aged previously in the literature. Kim et al. reported a case series with 28-case for WS. They found that the rate of women and men was the same, and the mean age was 48 years in the cases of WS. 35% of the patients had the diagnosis of HT. In the same study, 83% of patients had acute phalanx pain, 19% had hematuria and 11% had hypovolemic shock indicators (Kim et al., 2018). Our case was not compatible with Lenk's triad. In our report, the female patient was 50 years old and had a diagnosis of HT.

Daskalopoulos et al. reported a case series with 13-cases of WS, They reported that 5 patients were diagnosed with only ACT and 7 patients were diagnosed with ACT after USG (Daskalopoulos et al., 2003). Zhang et al. reported 165 cases in a case-series (Zhang et al., 2002). They reported that 135 cases were diagnosed with ACT, 100 cases were diagnosed with USG, 5 with magnetic resonance imaging (MRI) and 81 with angiography. Computerized tomography is the gold standard in spontaneous retroperitoneal hemorrhage, but in the first tomography, a little more than half of the cases are diagnosed (Zhang et al., 2002). The first imaging method is usually abdominal x-ray and then USG. Direct abdominal radiography is generally used to exclude other possible pathologies (Murphy et al., 2013). The diagnostic value of x-ray is too lower than ACT (Zhang et al., 2002; Kim et al., 2018). In our case, due to obesity and intense intraabdominal gas, the diagnosis could not be done with USG. In the ACT

images, bleeding was observed in the retroperitoneal area beginning from kidney. Hemodynamic parameters were within normal limits despite bleeding.

The treatment algorithm in WS is not clear. Zhang's study reported that they performed total nephrectomy in 113 patients, partial nephrectomy in eight patients, drainage in 17 patients, embolization in six patients and clinical follow-up in 16 patients (Zhang et al., 2002). Kim et al. reported they performed total nephrectomy for 11 cases of 13 patients (Daskalopoulos et al., 2003; Kim et al. 2018). Early diagnosis may decrease mortality and prevent unnecessary nephrectomy (Zhang et al., 2002). Nephrectomy is performed in hemodynamically

unstable cases, but embolization, radiofrequency ablation and cryoablation can be performed according to clinical condition (Flum et al., 2016). Nephrectomy was performed for our patient because the bleeding was opened to the retroperitoneal area.

Diseases in the patient's history may be a guide for rare clinical conditions. Therefore, advanced radiological imaging should be performed in the presence of clinical suspicion in unexplained abdominal pain.

This case is reported by obtaining consent from the patient and no support was provided from any institution.

## REFERENCES

- Baishya, R.K., Dhawan, D.R., Sabnis, R., Desai, M.R., 2011. Spontaneous subcapsular renal hematoma: A case report and review of literature. *Urol. Ann.* 3, 44.
- Daskalopoulos, G., Karyotis, I., Heretis, I., Anezinis, P., Mavromanolakis, E., Delakas, D., 2003. Spontaneous perirenal hemorrhage: A 10-year experience at our institution. *Int. Urol. Nephrol.* 36, 15-19.
- Flum, A.S., Hamoui, N., Said, M.A., Yang, X.J., Casalino, D.D., McGuire, B.B., Perry, K.T., Nadler, R.B., 2016. Update on the diagnosis and management of renal angiomyolipoma. *J. Urol.* 195, 834-846.
- Katabathina, V.S., Katre, R., Prasad, S.R., Surabhi, V.R., Shanbhogue, A.K., Sunnapwar, A., 2011. Wunderlich syndrome: Cross-sectional imaging review. *J. Comput. Assist. Tomogr.* 35, 425-433.
- Kendall, A.R., Senay, B.A., Coll, M.E., 1988. Spontaneous subcapsular renal hematoma: Diagnosis and management. *J. Urol.* 139, 246-249.
- Kim, J.W, Kim, J.Y., Ahn, S.T., Park, T.Y., Oh, M.M., Moon, D.G., Park, H.S., 2018. Spontaneous perirenal hemorrhage (Wunderlich syndrome): An analysis of 28 cases. *Am. J. Emerg. Med.* 37, 45-47. 45-47
- Murphy, G.S., Sparks, S.E., Goldberg, S.R., Morton, J.R., 2013. Spontaneous retroperitoneal hemorrhage in a dialysis patient. *J. Emerg. Med.* 44, 217-219.
- Vaddi, S.P., Reddy, V.P., Devraj, R., 2011. Wunderlich's syndrome in a tuberous sclerosis patient. *Indian J. Surg.* 73, 227-229.
- Virchow R., 1856. *Handbuch der speciellen Pathologie und Therapie*: Enke. 6.
- Zhang, J.Q., Fielding, J.R., Zou, K.H., 2002. Etiology of spontaneous perirenal hemorrhage: A meta-analysis. *J. Urol.* 167, 1593-1596.