



The Relationship Between Maxillary Third Molar Teeth and Maxillary Base Length Maksiller Üçüncü Molar Dişlerin Maksiller Kaide Uzunluğu İle İlişkisi

Sanaz Sadry¹, Cansu G. Koca²

¹Istanbul Aydın University, Faculty of Dentistry, Department of Orthodontics, İstanbul, Turkey.

²Uşak University, Faculty of Dentistry, Department of Oral, Maxillofacial Surgery, Uşak, Turkey.

Abstract

Objective: The aim of this study was to evaluate the position of the maxillary third molars and their relationship with the maxillary base length on panoramic and cephalometric radiographies.

Material-Method: 151 individuals (67 males, 84 females, mean age 19.02±1.62) who applied with different complaints to the Department of Oral and Maxillofacial Surgery and Orthodontics of Uşak and Istanbul Aydın University Faculty of Dentistry. Inclusion criteria were, patients over 18 years of ages, having unilateral or bilateral impacted maxillary third molars belonging to Class 3 and C category according to Arher classification and having cephalometric and panoramic radiographies. The positions of maxillary third molar teeth and their relationship with effective maxillary base length were examined in detail in cephalometric radiographies.

Results: The data obtained were evaluated with SPSS (22.0) package program. Mann-Whitney U Test was used for the analysis of the data and for the analysis of two-variable data. Maxillary third molar teeth examined with cephalometric and panoramic radiographies have no relation to maxillary base. In our study, Maxillary impacted third molars were found to have a rate of 48.3% in patients with skeletal class I 41.1% in patients with skeletal class II, and 10.6% in patients with skeletal class III. 70.2% of the maxillary impacted third molars were unilaterally; 29.8% of them were found to be bilaterally. The length of the maxilla base does not statistically affect the unilaterally or bilaterally impaction of the maxillary third molar teeth (P=0.735).

Conclusions: In the light of our study, it was seen that there is a relationship between the rate of impaction of maxillary third molar teeth and skeletal anomalies, and we can state that this finding is not statistically significant. For this reason, we believe that examining the maxilla mid-face and base length dimensions in larger populations can shed light on early detection of anomalies.

Keywords: Maxillary Third Molar, Maxillary Length, Cephalometric Radiography, Panoramic Image.

Özet

Amaç: Çalışmanın amacı, panoramik ve sefalometrik radyograflarda maksiller üçüncü molar dişlerin pozisyonlarının, maksiller kaide uzunluğu ile olan ilişkilerinin değerlendirilmesidir.

Materyal-Metot: Uşak ve İstanbul Aydın Üniversitesi Diş Hekimliği Fakültesi Ağız, Diş ve Çene Cerrahisi Anabilim Dalı ile Ortodonti Anabilim Dalı'na farklı şikayetler ile başvuru yapmış 151 hasta (67 erkek, 84 kadın, ortalama yaşı 19.02±1.62) dahil edilmiştir. Hastaların, 18 ile 30 yaş arasında olması, unilateral veya bilateral gömülü dişlere sahip olması ve sefalometrik ve panoramik radyograflarının alınmış olması, Archer sınıflamasına göre Sınıf 3 ve C kategorisine ait maksiller üçüncü molar dişlere sahip olması dahil edilme kriterleri olarak belirlenmiştir. Retrospektif özellik taşıyan bu çalışmada; maksiller üçüncü molar dişlerin pozisyonlarının, efektif maksiller kaide uzunluğu ile olan ilişkileri sefalometrik radyografilerde ayrıntılı olarak incelenmiştir.

Bulgular: Elde edilen veriler SPSS (22.0) paket programı ile değerlendirilmiştir. İki değişkenli verilerin analizi için 'Mann-Whitney U testi kullanılmıştır. Maksiller üçüncü molar dişlerin maksillanın efektif orta yüz uzunluğu ve kaide uzunluğu ile ilişkisinin olmadığı görülmüştür. Maksiller gömülü yirmi yaş dişlerin iskeletsel sınıf I kapanışı olan hastalarda %48,3, iskeletsel sınıf II kapanışa sahip olan hastalarda %41,1 ve iskeletsel sınıf III kapanışa sahip olan hastalarda ise %10,6 oranına sahip olduğu görülmüştür. Maksiller gömülü üçüncü molar dişin %70,2'si unilateral; %29,8'i bilateral olduğu saptanmıştır. Maksilla kaidesinin uzunluğu maksiller üçüncü molar dişlerin unilateral veya bilateral olarak gömülü kalmasını istatistiksel olarak etkilememektedir (P=0,735).

Sonuç: Çalışmamız verileri ışığında maksiller üçüncü molar dişlerin gömülü kalma oranı ile kapanış anomalileri arasında bir ilişki olduğu görülmüş olup bu bulgunun istatistiksel olarak anlamsız olduğunu belirtebiliriz. Bu sebeple, maksilla orta-yüz ve taban uzunluk boyutlarını daha büyük popülasyonlarda incelemek anomalilerin erken saptanmasına ışık tutabileceğine inanıyoruz.

Anahtar kelimeler: Maksiller Üçüncü Molar Dişler, Maksiller Uzunluk, Sefalometrik Radyografi, Panoramik Radyograf.

Introduction

Wisdom tooth surgery, one of the cornerstones of oral, dental and maxillofacial surgery, is known to be the most common operation performed by surgeons. The third molars are the teeth to become most frequently impacted, followed by the upper canine and lower premolar teeth, respectively. They may become impacted due to local and systemic factors as well as growth disorders. In addition, the most common reason for the 3rd molar teeth to become impacted is the fact that they are the last teeth to erupt, which leaves them with insufficient space for eruption. Wisdom tooth extraction is a terrifying occasion for many. These teeth, which leads to various dental diseases such as pericoronitis, infection, periodontal diseases, cavities, odontogenic cysts, even pathologic formations including tumoral ones in many patients who refuses to have their wisdom tooth extracted, also cause psychological trauma in some of the patients who have their teeth extracted to such an extent that they refuse to visit a dentist in their future dental problems (1, 2).

Panoramic radiographs are the first preferred method for evaluating the relations of the third molars with anatomic formations. Apart from its advantages, this method also comes with some disadvantages such as superposition of anatomical structures, being subjected to magnification, and lack of information in cross-sectional images. Cephalometric images play a part in cephalometric evaluation of craniofacial structures, as well as orthodontic and surgical treatment planning. They are used to evaluate the position of maxillary third molars and their relation to anatomical formations, as they provide more detailed information in identification of the relationship between cephalometric measurements and anatomic formations in the region, and offer more precise data before surgical procedures (3-7). It has now become inevitable to take cephalometric images and evaluate the image through various analysis methods in order to adopt an accurate treatment approach, Cephalometric radiography has virtually become a common language not only for diagnosis and treatment, but also for understanding the growth-development patterns of patients, identifying their stage of growth, and the interpretation of treatment results. Therefore, it is highly crucial for orthodontists to perform cephalometric analyzes with ease, speed and precision (8). Consequently, the position assessments of maxillary base and maxillary third molars should be performed very carefully before dental procedures, especially surgical procedures.

The aim of this study is to evaluate the maxillary base length, the mandibula-maxilla relationship, the relationship between the position of the maxillary third molars and maxillary base length on cephalometric and panoramic images.

Material and Methods

The study was examined and approved by Istanbul Aydın University Institute of Medical Sciences Non-Interventional Clinical Research Ethics Committee of (No: B.30.2AYD.0.00.00-50.06.04 / 67). Our study included of panoramic and lateral cephalometric images from 151 asymptomatic patients between the ages of 18 and 30

with upper impacted wisdom teeth, indication of surgical extraction, and physical status I according to American Society of Anesthesiologists (ASA), who were admitted to Uşak and İstanbul Aydın University Faculty of Dentistry Department of Orthodontics and Oral, Dental and Maxillofacial Surgery Clinic for treatment between 2015 and 2018. The study included patients with unilaterally and bilaterally impacted teeth with complete bone retention, The teeth were selected based on Archer's impacted wisdom tooth classification (9). Accordingly, the teeth were selected from class 3 and class C groups, namely from those in vertical position and in a Crown-neck relationship with the second molar. The inclusion criteria for our study are listed below.

1. Volunteers must be between the ages of 18-30
2. No history of orthodontic treatment or surgery
3. No history of any systemic diseases that affect the jaw-face development
4. Presence of bilateral impacted upper third molars
5. No history of tooth loss or extraction
6. Cephalometric and panoramic radiographs being clear enough to allow monitoring of the entire dentition
7. No local factors that lead to the impaction of the upper third molars
8. No loss of third molar with incomplete root development or adjacent second molar due to any reason,

Measurement and Evaluation

On panoramic images (Figure 1):

- Bone depth of the maxillary third molars,
- Angulation of the maxillary third molars to the second molar.

On cephalometry (Figure 2):

- Effective midface length of maxilla Co-A,
- Maxillary base length ANS-PNS.

"Informed Voluntary Consent Form" and "Patient Follow-Up Form" were drawn up for all the patients. This study was conducted with the approval of the Non-Interventional Research Ethics Committee. There was no gender discrimination in patient selection. Cephalometric radiographs of all individuals included in the study were obtained in İstanbul Aydın University Faculty of Dentistry Department of Dental and Maxillofacial Radiology using Planmeca 2011-05 Proline Pan/Ceph X-Ray unit (Planmeca, Helsinki, Finland). The distance between the ray source and radiograph was standardized as 160 cm, and the distance between the common plane and radiograph as 16 cm. During x-ray, teeth were set to centric occlusion and the rest positions of lips were checked to prevent any potential soft tissue distensions. The Frankfort Horizontal Plane (FH plane) of the head was positioned to be parallel to the ground, and was fixated via the ear rods of cephalostat. Radiographs were obtained by adjusting the x-ray device to emit beams per second and in a way that kVp is in line with bone ages. Patient records were digitalized using NemoCeph NX (Nemotech, Madrid, Spain) computerized cephalometric analysis system and program.

Skeleton classification was done according to ANB angle, as shown in Table 1. The effective maxilla length was calculated by measuring the distance between Co-A values (Figure 2).

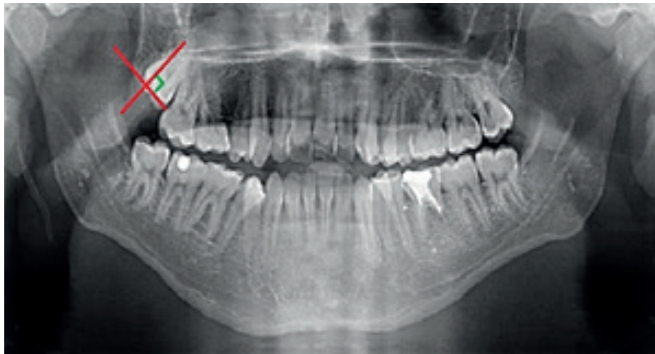


Figure 1. Class 3 and class C groups according to Archer (1975) classification.

In panoramic images, it is seen that 2 lines intersect at 90 degrees, parallel to the long axis and occlusal plane of the third molar tooth embedded in the maxillary.

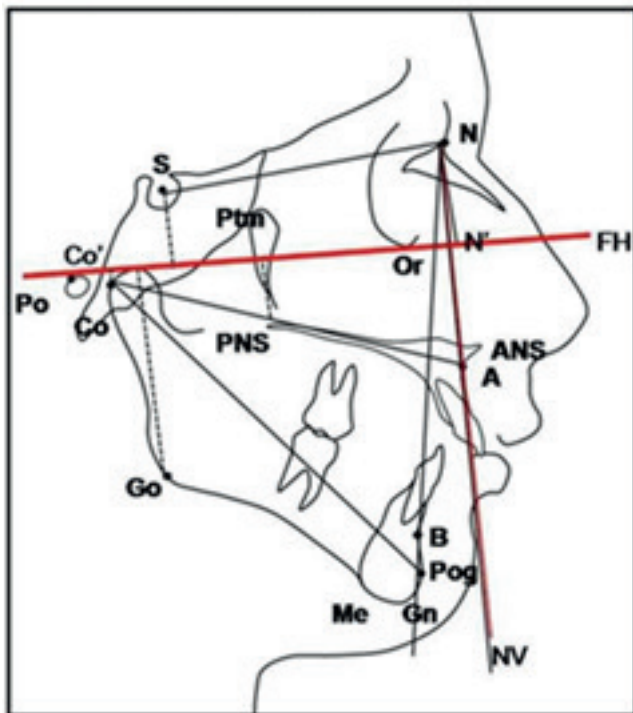


Figure 2. Cephalometric drawing

1. Subspinal Point (A): Spina nasalis is the deepest point of concavity between anterior and prosthion points.
 2. Condylion (Co) Mandibular condyle is the highest point.
 3. Spina nasalis anterior(ANS): Anterior and extreme end of anterior nasal spinana
 4. Spina nasalis posterior(PNS): Rear endpoint of hard palate
- Co-A (Effective Maxillary Length): The distance between the condyle point and the A point
 •ANS-PNS: The distance between ANS and PNS points. Palatal length.

Table 1. Patient classification was done according to ANB angle. The classification consists of 3 separate groups

Skeletal class 1	ANB: 0°-4°
Skeletal class 2	ANB>4°
Skeletal class 3	ANB<0°

Statistical Analysis

The data were analyzed on SPSS 22.0 (Statistical Package for Social Sciences, Chicago, Illinois, ABD) package program. Data analysis was assessed using chi-square, Mann Whitney U, Wilcoxon and Kruskal Wallis tests. Significance level was considered statistically significant for p<0.05.

Results

The study was conducted on 162 maxillary third molars from 84 female (55.6%) and 67 (44.4%) male patients, with a total of 151. Of the 151 patients included in the study, 45 had bilateral and 106 had unilateral maxillary third molars. Out of 67 male patients, 22 (48.9%) had bilateral and 45 (42.5%) had unilateral maxillary third molars; out of 84 female patients, 23 (51.1%) had bilateral and 61 (57.5%) unilateral maxillary third molars (Table 2). Skeletal malocclusion classification and CO-A are shown in Table 3. Comparison of the 3 groups according to the skeletal classification and CO-A variable was found to be statistically significant. Both Groups 1 and 2 and Groups 2 and 3 were found to be different (P=0.013). The molar status being unilateral or bilateral did not lead to any statistical difference in the CO-A variable (Table 4, p=0.329). Skeletal malocclusion classification and ANS-PNS are shown in Table 5. Comparison of the Skeletal Classes in accordance with the ANS-PNS variable, revealed on statistically significant difference between the 3 groups (p=0.231). Likewise, the molar status being unilateral or bilateral did not lead to any statistical difference in the ANP-PNS variable (Table 6, p=0.735).

Table 2. Frequency and percentage distributions of categorical variables in the study

		Frequency	Percentage
Gender	1.0	67	44.4
	2.0	84	55.6
Skeletal Class	1.0	73	48.3
	2.0	62	41.1
	3.0	16	10.6
Molar	unilateral	106	70.2
	bilateral	45	29.8

Table 3. CO-A and Skeletal Class 1, 2, 3

	Molar	N	Minimum	Maximum	Mean	Std. Deviation	Mean Rank	Mann-Whitney U	p
Co-A	Unilateral	106	70.0	120.0	89.151	9.7705	73.74	2145.5	0.329

Table 4. CO-A unilateral and bilateral

	Molar	N	Minimum	Maximum	Mean	Std. Deviation	Mean Rank	Mann-Whitney U	p
Co-A	Unilateral	106	70.0	120.0	89.151	9.7705	73.74	2145.5	0.329
	Bilateral	45	68.0	115.0	91.200	10.0467	81.32		

Table 5. ANS-PNS and Skeletal Class 1, 2, 3

	Skeletal Class	N	Minimum	Maximum	Mean	Std. Deviation	Mean Rank	Kruskal Wallis	p
ANS-PNS	1	73	50.0	74.0	59.411	5.1662	73.58	2.932	0.231
	2	62	50.0	75.0	60.065	5.1466	82.19		
	3	16	55.0	70.0	58.250	4.5240	63.09		

Table 6. ANS-PNS unilateral and bilateral

	Molar	N	Minimum	Maximum	Mean	Std. Deviation	Mean Rank	Mann-Whitney U	p
ANS-PNS	Unilateral	106	50.0	74.0	59.462	4.6725	76.77	2303	0.735
	Bilateral	45	50.0	75.0	59.778	6.0185	74.18		

Discussion

Teeth that failed to erupt into the dental ark in time and take their place in normal occlusion and are completely or partially retained in the bone or soft tissue are defined as impacted (10-12). Difficulty in wisdom teeth taking their place in the dental arch depends on inadequate space as well as the fact that the dentition and eruption conditions and the distance and direction they have moved during eruption differ from other teeth. The upper wisdom teeth do not fall within the scope of orthodontic theory, and they complete the eruption process with a completely opposite movement. The upper second molar erupt in a downward and forward direction, while the upper wisdom teeth can make a triple movement in downward, backward and outward directions. This complex movement is often delayed in modern humans, and the completion of the normal formation of tubercle maxilla causes the upper wisdom tooth to remain impacted. Even if there is sufficient room for the wisdom tooth to erupt, some local and systemic factors adversely affect the eruption of these teeth into the occlusal plane (12, 13). However, no studies have been conducted on the direct effect of maxilla base length and effective maxilla length on the bilateral or unilateral impact of the upper wisdom teeth, or any correlation between them. We attribute this to the absence of a norm with which the effective maxilla length can be classified. Therefore, our study intended to investigate the relationship between skeletal malocclusion classification and the effective length of the maxilla. That being the case, our study is unique in that it will offer a different perspective on the impaction pattern of the maxillary third molars.

Teeth do not require intervention when they erupt into the correct position, do not damage the surrounding tissues and cause any complaints. In cases of inadequate space on the dental arch, tooth eruption can be obstructed by the gingiva, bone or other adjacent teeth. Impacted third molars may be in close relationship with different anatomical structures in their region (14, 15). A potential disproportion between the tooth widths and the size of the jawbone in dental-jaw system that is explained by the Orthodontic and Mendelian theories frequently resulted in the impaction of these teeth. Consequently, surgical operations on these teeth have now become a routine procedure (16-18). Among the theories that explain the causes of impaction, the most reasonable one is the decrease in the mandible and maxilla sizes depending on the extent of evolution. Thus, there is not enough space left in the

jaws for lower or upper wisdom teeth (19). Development of wisdom teeth begins in parallel with the growth of the jawbone (20). Genetic and environmental factors can affect the growth of the jaws and the movement of the dental lamina, resulting in interactions between these two tissues and thus changes in wisdom teeth formation. The effects of environmental factors and teratogens on tooth development are referred as changes in tooth shape, width and position (21, 22).

In many studies, mandibular third molars have been reported to be the most frequently impacted teeth among the third molar teeth (23, 24). However, there are also studies reporting that maxillary third molar teeth have a higher incidence of impaction (23, 24). Venta et al. noted that the incidence of impaction of molars in societies varies between 22% and 66%. Sağlam et al., on the other hand, reported that the most common fully impacted teeth among the Turkish population are the mandibular third molar in males and upper third molar in females, and that the incidence of impaction in Turkish population is 11% (23).

Our study did not find any difference between genders. In parallel with other studies in the literature (25, 26), Tuğsel et al. (23) also make no mention of a difference in the distribution of impacted teeth with regard to gender. In the study carried out by Dural et al. (27), the incidence of impacted teeth was found to be higher in females than in males, and this was statistically confirmed. Maxillary third molar teeth were most commonly observed in mesioangular and vertical positions, while the upper third molar teeth were most commonly seen in vertical position in parallel with the findings of Tuğsel et al. (23). They reported observing a smaller number of distoangular positions, and rarely horizontal positions (28). Hattab et al. noted that inadequate retromolar space was notably related to tooth impaction, and that even in the case of sufficient retromolar space, an impaction rate of 17% was observed nonetheless (29).

We are of the opinion that the maxillary pedestal length (ANS-PNS) being statistically the same in all groups, and the effective midface length (CO-A) of skeletal class 2 patients being longer than that of other groups is related to the position of the condyl. The fact that whether the impacted maxillary third molar is unilateral or bilateral has no statistical relationship with the base length and the effective mid-face length of the maxilla. Avsever's (29) thesis study investigates the relationship between maxillary and mandibular third

molar teeth with maxillary sinus and mandibular canal on panoramic radiographs and computed tomographic images. In this study, all third molars with or without maxillary sinus were included in scope of the evaluation. There is a limited number of studies on this subject available in the literature. There is no relationship between maxillary third molars and maxillary base, as similarly found by our study.

Conclusion

In conclusion, our study demonstrated that there is a difference in the impact of wisdom teeth depending on the anomalies, but these have been found to be statistically insignificant. We think that examining the mid-face and base length dimensions of the maxilla in larger populations in order to distinguish their relationship with wisdom teeth impaction can shed light on early detection of anomalies.

References

1. Lim AA, Wong CW, Allen JC, Jr. Maxillary third molar: patterns of impaction and their relation to orofacial perforation. *Journal of Oral and Maxillofacial Surgery* 2012; 70(5): 1035-1039.
2. Kruger E, Thomson WM, Konthasinghe P. Third molar outcomes from age 18 to 26: findings from a population-based New Zealand longitudinal study. *Oral Surgery, Oral Medicine, Oral Pathology and Oral Radiology* 2001; 92(2): 150-155.
3. Koseglu BG, Gumru O, Kocaelli HA. Lower third molar displaced in the sublingual space. *Dentomaxillofacial Radiology* 2002; 31(6): 33-393.
4. Walker L, Enciso R, Mah J. Three-dimensional localization of maxillary canines with cone-beam computed tomography. *American Journal of Orthodontics and Dentofacial Orthopedics* 2005; 128(4): 418-423.
5. Bouquet A, Coudert JL, Bourgeois D, Mazoyer JF, Bossard D. Contributions of reformatted computed tomography and panoramic radiography in the localization of third molars relative to the maxillary sinus. *Oral Surgery, Oral Medicine, Oral Pathology and Oral Radiology* 2004; 98(3): 342-347.
6. Hazza'a AM, Albashaireh ZS, Bataineh A. The relationship of the inferior dental canal to the roots of impacted mandibular third molars in a Jordanian population. *Journal of Contemporary Dental Practice* 2006; 7(2): 71-78.
7. Quek SL, Tay CK, Tay KH, Toh SL, Lim KC. Pattern of third molar impaction in a Singapore Chinese population: a retrospective radiographic survey. *International Journal of Oral and Maxillofacial Surgery* 2003; 32(5): 548-552.
8. Gregston MD, Kula T, Hardman P, Glaros A, Kula K. A comparison of conventional and digital radiographic methods and cephalometric analysis software in hard tissue. *Semin Orthod* 2004; 10(3):204-211.
9. Archer WH. *Oral and Maxillofacial Surgery*. 5th ed. Vol I. Philadelphia: WB Saunders Co; 1975. p. 321-335.
10. Song F, O'meara S, Wilson P, Golder S, Kleijnen J. The effectiveness and cost-effectiveness of prophylactic removal of wisdom teeth. *Health echnol Assess*. 2000; 4 (15):1-55.
11. Peterson LJ, Ellis E, Hupp JR, Tucker MR. *Contemporary Oral and Maxillofacial Surgery An Affiliate of Elsevier Science. America*. 4th Ed. Mosby year book 2003 p. 425-435.
12. Türker M, Yücetaş, Ağız Diş Çene Hastalıkları ve Cerrahisi. 3.Baskı. Özyurt Matbaacılık İnş. Taah. San. ve Tic. Ltd. Şti. 2004.
13. Türker M.N, Anadolu'da değişik devrelerde yaşamış insanlarda gömülü 20 yaş dişleri ve M3 mesafesinin değerlendirilmesi. *A.Ü. Diş Hek. Fak. Derg.* 198; 8: 37-48.
14. Avsever İH. Üçüncü Büyük Azı Dişlerinin Anatomik Oluşumlarla İlişkilerinin Tespitinde Panoramik Radyografi ve Dental Programlı Bilgisayarlı Tomografi Bulgularının Değerlendirilmesi. Sağlık Bilimleri Enstitüsü, Oral Diagnoz ve Radyoloji Anabilim Dalı. Doktora Tezi, Ankara: Gülhane Askeri Tıp Akademisi, 2007. Şekerci AE. Mandibular Gömülü Üçüncü Büyük Azı Dişleri ile Mandibular Kanal Arasındaki İlişkinin Dental Volümetrik Tomografi ile Değerlendirilmesi. Sağlık Bilimleri Enstitüsü, Diş Hastalıkları ve Tedavisi Anabilim Dalı. Doktora Tezi, Kayseri: Erciyes Üniversitesi, 2012.
15. Şekerci AE, Mandibular Gömülü Üçüncü Büyük Azı Dişleri ile Mandibular Kanal Arasındaki İlişkinin Dental Volümetrik Tomografi ile Değerlendirilmesi. Sağlık Bilimleri Enstitüsü, Diş Hastalıkları ve Tedavisi Anabilim Dalı. Doktora Tezi, Kayseri: Erciyes Üniversitesi, 2012.
16. Tetsch P, Wagner W. *Operative Extraction of Wisdom Teeth*. Worcester: Ebeneser Baylis & Son Ltd. 1990.
17. Lübbers TH, Matthews F, Damerau G, Kruse LA, Obwegeser AJ, Grätz WK, Eyrich KG. Anatomy of impacted lower third molars evaluated by computerized tomography: is there an indication for 3-dimensional imaging? *Oral Surg Oral Med Oral Pathol Oral Radiol Endod*. 2011; 111 (5):547-550.
18. Ten Cate, AR, *Oral Histology: Development, Structure, and Function*. 5th ed. Mosby, St Louis. 1998 pp. 32-45.
19. Karadzov OM, Sedlecki-Gvozdenovic, SD, Demajo M, Milovanovic OK. The effects of X-ray irradiation of the head region of eight-day-old rats on the development of molar and incisor teeth *Strahlentherapie*. 1985; 161(5): 448-452.
20. Kronmiller JE, Beeman CS, Nguyen T, Bemdt W. Blockade of the initiation of murine odontogenesis in vitro by citral, an inhibitor of endogenous retinoic acid synthesis. *Arch Oral Biol*. 1995;40 (7): 645-652.
21. Alling CC, Helfrick JF, Alling RD, *Impacted Teeth*, WB Saunders Company, Philadelphia, 1993.
22. Peterson LJ, Ellis E, Hupp JR, Tucker MR, *Contemporary Oral and Maxillofacial Surgery*, The CV Mosby Company, ST. Louis 1988.
23. Tuğsel Z, Kandemir S, Küçükler F, Üniversite öğrenen cilerinde üçüncü molarların gömüklülük durumlarının değerlendirilmesi, *Cumhuriyet Ün. Dişhek. F. Der.* 4 (2);102-105;2001.
24. Türker MN, Yirmi yaş dişlerinin patogenezi, fokal

infeksiyon yönünden tetkiki ve çenede duruş pozisyonlarına göre istatistik değerlendirmeleri, Doktora Tezi, Ankara Ün,Tıp Fak. Dişhekimliği Yük.Okulu, Ağız ve Çene Şirürjisi Böl., Ankara,1971.

25. Venta I, Turtola L, Ylipaavalniemi P. Radiographic follow-up of impacted third molars from age 20 to 32 years , Int J Oral Maxillofac Surg , 2001;30(4) : 54-57.

26. Schersten E, Lysell L, Rohlin M. Prevalence of impacted third molars in dental students, Swed. Dent. J. 1989; 13(5):7-13.

27. Dural S, Avcı N, Karabıyıköğlü T. Gömük dişlerin

görülme sıklığı, çenelere göre dağılımları ve gömülü kalma ne denleri, Sağ Bil Arş Derg. 1996;7 (16): 127 – 133.

28. Hattab FN, Abu Alhaija ESJ. Radiographic evaluation of mandibular third molar eruption space , Oral Surg Oral Med Oral Pathol Oral Radiol Endod 1999; 88(5) : 285 – 91.

29. Avsever İH. Üçüncü Büyük Azı Dişlerinin Anatomik Oluşumlarla İlişkilerinin Tespitinde Panoramik Radyografi ve Dental Programlı Bilgisayarlı Tomografi Bulgularının Değerlendirilmesi. Sağlık Bilimleri Enstitüsü, Oral Diagnoz ve Radyoloji Anabilim Dalı. Doktora Tezi, Ankara: Gülhane Askeri Tıp Akademisi, 2007.